

DOI: <https://doi.org/10.5554/22562087.e1002>

# Inverted P waves: harmless or harbinger of doom?

## *Ondas P invertidas: ¿Inocuas o un mal presagio?*

Sandeep Khanna<sup>a,c</sup> , Roshni Sreedharan<sup>b,d</sup> , Carlos Trombetta<sup>a,b</sup> , Sergio Bustamante<sup>a</sup>

<sup>a</sup> Department of Cardiothoracic Anesthesiology, Anesthesiology Institute, Cleveland Clinic Foundation, Cleveland, USA.

<sup>b</sup> Department of General Anesthesiology, Anesthesiology Institute, Cleveland Clinic Foundation, Cleveland, USA.

<sup>c</sup> Department of Outcomes Research, Anesthesiology Institute, Cleveland Clinic Foundation, Cleveland, USA.

<sup>d</sup> Department of Intensive Care and Resuscitation, Anesthesiology Institute, Cleveland Clinic Foundation, Cleveland, USA.

**Correspondence:** Department of Cardiothoracic Anesthesiology, Department of General Anesthesiology and Department of Outcomes Research, Anesthesiology Institute, Cleveland Clinic Foundation, 9500 Euclid Avenue, E3-108, Cleveland Clinic Foundation, Cleveland, Ohio 44122. **Email:** khannas@ccf.org

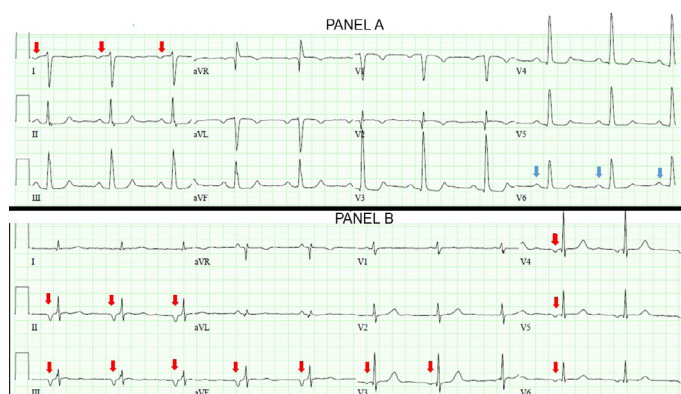
**How to cite this article:** Khanna S, Sreedharan R, Trombetta C, Bustamante S. Inverted P waves: harmless or harbinger of doom?. Colombian Journal of Anesthesiology. 2022;50:e1002.

P-waves represent atrial depolarization and appear upright in electrocardiographic leads I, II and V3-6, when they originate from the sinoatrial-node. New onset inverted P-waves, may result from benign or potentially life-threatening conditions. Anesthesiologists often have to decide if further work up is necessary in such circumstances, especially in symptomatic patients. We present two examples.

**Image A**, an electrocardiogram from a patient who developed nausea while recovering in the post-anesthesia-care-unit after undergoing an uneventful cystoscopy, demonstrates inverted P-waves in lead I (red-arrows) and upright P-waves in lead V6 (blue-arrows). As P-wave polarity should be similar in leads I and V6, the inconsistency in Image-A suggests reversal of left-arm and right-arm electrode positions.<sup>(1)</sup> Correct electrode placement rectified P-wave inversion and ondansetron administration ameliorated nausea.

**Image B** demonstrates prominent inverted P-waves in inferior-leads II, III, aVF and precordial-leads V3-6 (red-arrows). This suggests retrograde atrial depolarization and in conjunction with a heart-rate <70 beats/min, this pattern represents an atrioventricular-junctional-rhythm. Atrioventricular-junctional-rhythm may be a manifestation of sinus-node-dysfunction, myocardial-infarction, or digoxin-toxicity.<sup>(2)</sup> The electrocardiogram presented in **Image B** is from a patient who endorsed feeling nauseated in the post-anesthesia-care-unit after undergoing an endoscopy under propofol-anesthesia. This patient accidentally continued his oral digoxin therapy while completing a clarithromycin-based Helicobacter-Pylori eradication regimen.

Clarithromycin-induced inhibition of P-glycoprotein, an efflux pump that influences digoxin pharmacokinetics, results



**Image A:** An electrocardiogram from a patient who developed nausea while recovering in the post-anesthesia-care-unit after undergoing an uneventful cystoscopy.

**Image B.** Prominent inverted P-waves in inferior-leads II, III, aVF and precordial-leads V3-6 (red-arrows).

**SOURCE:** Authors.

in increased gut absorption and decreased renal excretion of digoxin. This drug interaction can potentially precipitate digoxin-toxicity. As patients often present with non-specific symptoms such as nausea, abdominal pain, confusion, headache or dizziness, diagnosis of digoxin-toxicity necessitates a high index of suspicion. Electrocardiographic manifestations include severe bradyarrhythmias and ventricular tachyarrhythmias. Although digoxin serum levels do not correlate with severity of toxicity, they help corroborate the diagnosis. In addition to atropine administration and institution of inotropic support, symptomatic and hemodynamically unstable digoxin-induced

bradyarrhythmias may warrant early administration of digoxin-specific-antibody-fragments.<sup>(3)</sup>

## ACKNOWLEDGMENTS

### Author's contributions

**SK:** Conception of project, planning and final writing of manuscript.

**RS, CT** and **SB:** Conception of project, approval of manuscript.

### Assistance with the study

None declared.

### Financial support and sponsorship

None declared.

### Conflicts of interest

None declared.

### Presentation

None declared.

### Conflict of Interest

No external funding and no competing interests declared.

## REFERENCES

1. Chapter: Mirvis DM, Goldberger AL: Electrocardiography, Braunwald's Heart Disease: A Textbook of Cardiovascular Medicine, 11th edition. Edited by Zipes DP, Libby P, Bonow RO, Mann DL, Tomaselli GF, Braunwald E. Philadelphia, Elsevier, 2019, pp 117-53
2. Atlee JL. Perioperative cardiac dysrhythmias: diagnosis and management. *Anesthesiology*. 1997;86(6):1397-424. doi: <https://doi.org/10.1097/00000542-199706000-00026>
3. Eichhorn EJ, Gheorghiade M. Digoxin. *Prog Cardiovasc Dis*. 2002 Jan-Feb;44(4):251-66. doi: <https://doi.org/10.1053/pcad.2002.31591>