



Colombian Journal of Anesthesiology

Revista Colombiana de Anestesiología

www.revcolanest.com.co



Review

Regional anesthesia in pediatrics – Non-systematic literature review[☆]



Angela María Ríos-Medina^{a,*}, Juliana Caicedo-Salazar^b, María Isabel Vásquez-Sadder^c, Oscar David Aguirre-Ospina^d, María Patricia González^e

^a Specialist in Anesthesia and Resuscitation, Universidad de Caldas, Caldas University Professor, Anesthesiologist Clínica Confamiliar and Cancer League, Pereira, Colombia

^b Specialist in Anesthesia and Resuscitation, Universidad de Caldas, Anesthesiologist Clínica Confamiliar, Pereira, Colombia

^c Specialist in Anesthesia and Resuscitation, Universidad CES, Clinical Anesthesiologist CES, Coordinator of the Regional Anesthesia Committee S.C.A.R.E., LASRA Delegate, Medellín, Colombia

^d Specialist in Anesthesia and Resuscitation, Universidad de Caldas, Caldas University Professor, Anesthesiologist Hospital SES, Manizales, Colombia

^e Specialist in Anesthesia and Resuscitation, CES University, Pain and Palliative Care Specialist, Anesthesiologist and Coordinator of Clinical Surgery, CES, Medellín, Colombia

ARTICLE INFO

Article history:

Received 22 July 2014

Accepted 17 February 2015

Keywords:

Anesthesia, conduction

Pediatrics

ultrasonography

Neuromuscular blocking agents

Anesthetics, local

ABSTRACT

Introduction: The use of pediatric regional anesthesia has grown to become the standard of care, because of its effective pain control, improved safety profile of the local anesthetic agents, in addition to the introduction of ultrasound.

Objective: To perform a non-systematic review of pediatric regional anesthesia.

Methods and materials: A search was conducted on the available scientific evidence in databases (Pubmed/Medline, ScienceDirect, OVID, SciELO), for a non-systematic review.

Conclusions: The use of pediatric regional anesthesia has increased due to its notable effect on pain management and furthermore as a result of the incremented use of ultrasound technology.

© 2015 Sociedad Colombiana de Anestesiología y Reanimación. Published by Elsevier España, S.L.U. All rights reserved.

Anestesia regional en pediatría – Revisión no sistemática de la literatura

RESUMEN

Introducción: El uso de anestesia regional en niños ha aumentado hasta convertirse en estándar de manejo, debido al efectivo control del dolor, mejor perfil de seguridad de anestésicos locales y a la implementación del ultrasonido.

Palabras clave:

Anestesia de conducción

Pediatría

[☆] Please cite this article as: Ríos Medina AM, Caicedo Salazar J, Vásquez Sadder MI, Aguirre Ospina OD, González MP. Anestesia regional en pediatría – Revisión no sistemática de la literatura. Rev Colomb Anestesiolog. 2015;43:204-213.

* Corresponding author at: Calle 10 No. 12B-30 Apartamento 704 Torre 2, Pereira, Colombia.

E-mail address: lunavero@yahoo.com (A.M. Ríos-Medina).

2256-2087/© 2015 Sociedad Colombiana de Anestesiología y Reanimación. Published by Elsevier España, S.L.U. All rights reserved.

Ultrasonografía
Bloqueantes neuromusculares
Anestésicos locales

Objetivo: Realizar una revisión no sistemática sobre evidencia científica disponible en anestesia regional pediátrica.

Métodos y materiales: Se realizó una búsqueda, sobre la evidencia científica disponible, en bases de datos (Pubmed/Medline, ScienceDirect, OVID, SciELO), para realizar una revisión no sistemática.

Conclusiones: El aumento en el uso de la anestesia regional pediátrica, se debe a que proporciona control adecuado del dolor y al uso del US. La realización de bloqueos en niños anestesiados o sedados es más segura que en pacientes despiertos.

© 2015 Sociedad Colombiana de Anestesiología y Reanimación. Publicado por Elsevier España, S.L.U. Todos los derechos reservados.

Introduction

Notwithstanding the benefits of pediatric regional anesthesia (PRA), just a few practitioners originally used it. During the last decade, the use of PRA has grown¹, due to the introduction of local anesthetics (LA) with improved profiles and tools such as ultrasonography that provides improved safety and has been associated with better nerve blocks². However, with the exception of ilio-hypogastric and ilio-inguinal nerve blocks (II-IH), the safety advantages of ultrasound (US) over the traditional techniques have not been proven in children because of the limited number of trials³.

PRA provides intra- and postoperative anesthesia and is considered an integral part of the pain management guidelines⁴, in addition to preventing the harmful effects of improper pain management⁵.

Ultrasound guidance is not totally risk-free. A number of trials have shown that a practitioner that begins training may make mistakes when visualizing the needle and as a result of inadvertent probe movements. For this reason, the American Society of Regional Anesthesia prepared a document recommending the inclusion of US-guided regional anesthesia training as part of the medical school syllabus⁶.

The purpose of this article was to review the literature on the key aspects of PRA techniques.

Methodology

A non-systematic literature search was performed using PUBMED/MEDLINE, ScienceDirect and OVID, based on the terms "regional anesthesia", "pediatric", "ultrasound", and "new local anesthetics". The search and the selection of articles were done in an independent manner, and were restricted to meta-analysis, systematic reviews, Cochrane reviews, clinical essays, and non-systematic reviews. The date of publication was not limited and no Spanish articles were included.

Historical evolution

The history of PRA began with the discovery of the anesthetic properties of cocaine. Bier introduced spinal anesthesia and two of his patients were children⁷. Gaston Labat began to teach

RA and wrote the book: *Regional anaesthesia: Its techniques and clinical applications*⁸.

The number of PRA reports has increased as pediatric anesthesia has evolved. Despite the considerable interest in PRA since 1980, its use was not generalized because general anesthesia was the standard, in addition to the existing concern about causing neurological injury⁹ to the sedated or anesthetized patient.

In 1998 over 50 pediatric anesthesiologists published an article¹⁰ showing that the outcome of a nerve block in an anesthetized child is safer than in a patient that is awake and excited. Other authors wrote an editorial called *Regional Anesthesia: children are different*, stressing the need to avoid considering pediatric patients as small adults¹¹. Later on, other papers were published describing new techniques, local anesthetics, and adjuvants^{12,13}. Today, RA represents an unquestionable advantage for pain control and plays a relevant role in clinical practice¹⁴.

Neuraxial blocks

Epidural and caudal

Epidural analgesia, including the caudal approach, has been the cornerstone for postoperative pain management in children. It is currently indicated for open chest surgery, major abdominal and spine surgery. The current trend in lower limb surgery is the use of peripheral nerve blocks, including perineural catheters¹⁵.

The risk of serious complications is 1:10,000 in epidural anesthesia and 0.2:10,000 in caudal anesthesia¹⁵. The anatomic characteristics of children should be considered in order to avoid accidentally puncturing important anatomical structures⁶.

Neuraxial blocks in children based on anatomical landmarks are safe and currently there is no evidence of the need for the routine use of ultrasound^{16,17}.

The loss of resistance in the smaller patients should be done with air because it facilitates the identification of any unintended puncture of the dura mater⁶. The advancement of caudal catheters in neonates is not recommended because of the high rates of contamination¹⁵. In older patients, the recommended approach is from the low lumbar area, ideally inserting the catheter as close as possible to the surgical site. Visualizing the tip of the catheter using ultrasound,

radiology aids, and electrical stimulation are all modern techniques used to confirm the position of the catheter^{6,15}.

Spinal anesthesia

This approach was quite popular early in the twentieth century and had a comeback three decades ago, due to the successful results shown in preterm babies undergoing herniorrhaphy, since these babies were at high risk of post-operative apnea. Spinal anesthesia is safe for infants, school children and adolescents¹⁸ undergoing lower limb surgery and any procedure below the umbilicus^{18,19}.

The contraindications are: puncture site infection, rise in intracranial pressure, degenerative axon disease and severe hypovolemia^{18,20}.

The key limitation is the length of time – between 70 and 90 min because of the increased CSF volume, heart rate, and blood flow, both through the bone marrow as through epidural space. In order to do a spinal puncture, sedation or prior administration of a local anesthetic is required to control movement¹⁸.

The puncture is made at L4–L5 or L5–S1, in lateral decubitus or with the patient sitting down. The injection shall be administered in over 20 s and the Trendelenburg position should be avoided due to the risk of total spinal anesthesia. The local anesthetic agents of choice are levobupivacaine and ropivacaine, both at a 0.5 mg/kg dose¹⁸.

Peripheral nerve block

All of the peripheral nerve blocks performed in adults may also be administered to children¹⁶.

General considerations

It is absolutely crucial to define whether the block will be done under sedation or general anesthesia²¹. Fasting time should be considered, keeping in mind that trauma children should be considered as having a full stomach²². If a neurological injury is suspected, it should be documented with a physical examination prior to administering the block. The extent of neurological injury may be assessed early during the post-operative period, using low LA concentrations.

The likelihood of compartment syndrome is not a contraindication for regional anesthesia since the block does not mask its diagnosis because of the severity of the pain and also because there are diagnostic aids to confirm the condition, such as infrared spectroscopy²³.

The presence of infection does not represent an absolute contraindication either, and the block may be administered at a site away from the surgical area.

Technical considerations

A comfortable position is critical, with the ultrasound screen facing the operator²⁴. The anatomic structures in children are superficial and the recommendation is to use a high frequency lineal probe (>13 MHz). Echogenic blunt-tip 22–24 G needles, with a separate injection line are the most suitable²¹.

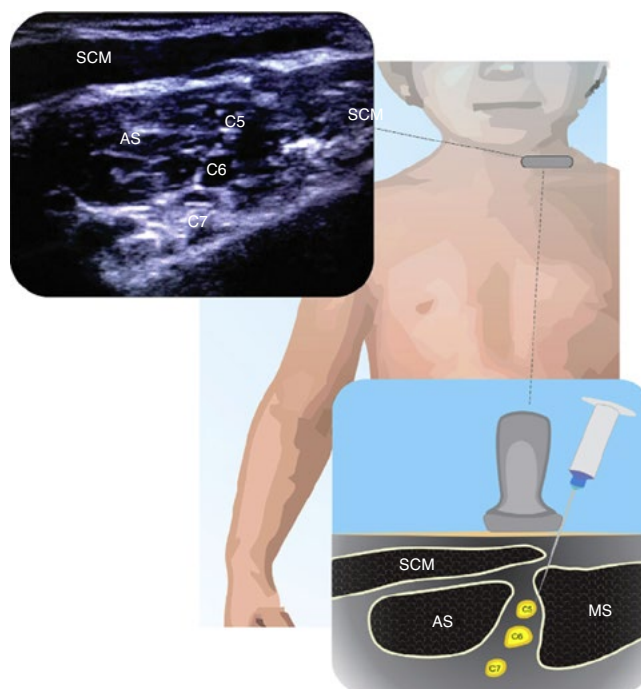

Fig. 1 – Interscalene block. Illustrates the anatomy of the nerve roots – C5, C6 and C7 – lateral to the sternocleidomastoid muscle (SCM) within the interscalene groove (anterior scalene muscle (AS) and middle scalene (MS)).

Fuente: Authors.

Upper limb blocks

The following are the most common ultrasound-guided brachial plexus approaches.

Interscalene

There are few publications on the interscalene block approach in children²⁵. This is a useful approach for shoulder procedures and subcapital fractures of the humerus. Fig. 1 illustrates the anatomy of the C5–C7 nerve roots within the interscalene groove. The block may be done both inside and outside the plane, but the superficial location of these structures requires careful needle manipulation. The volume and concentration of the LA depend on the patient and the procedure²¹.

Supraclavicular

This has been a controversial block because of the proximity of the subclavian vein and the pleura. The use of ultrasound has increased this approach and the recommendation is to proceed from the lateral to the medial plane. The supraclavicular approach is indicated for procedures below the mid humeral level. As compared against the infraclavicular approach, the supraclavicular has a lower latency and higher

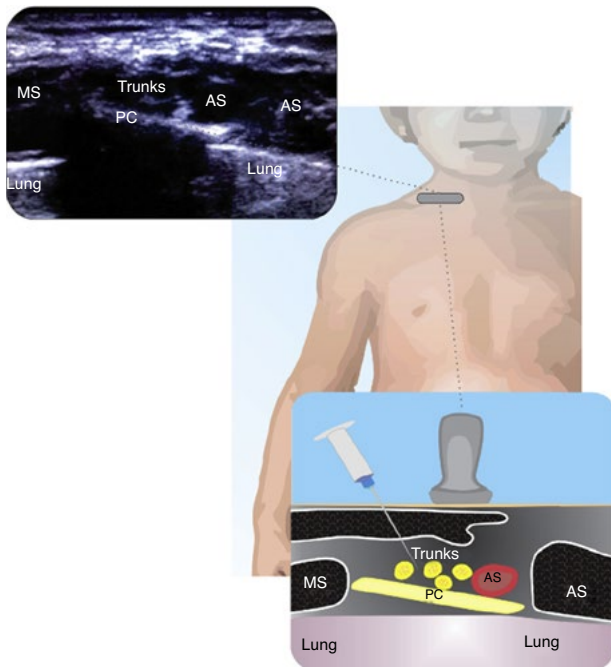


Fig. 2 – Supraclavicular block. Illustrates the relationship of the subclavian artery trunks and divisions, the lung and the first rib; middle scalene (MS) and anterior scalene (AS). Fuente: Authors.

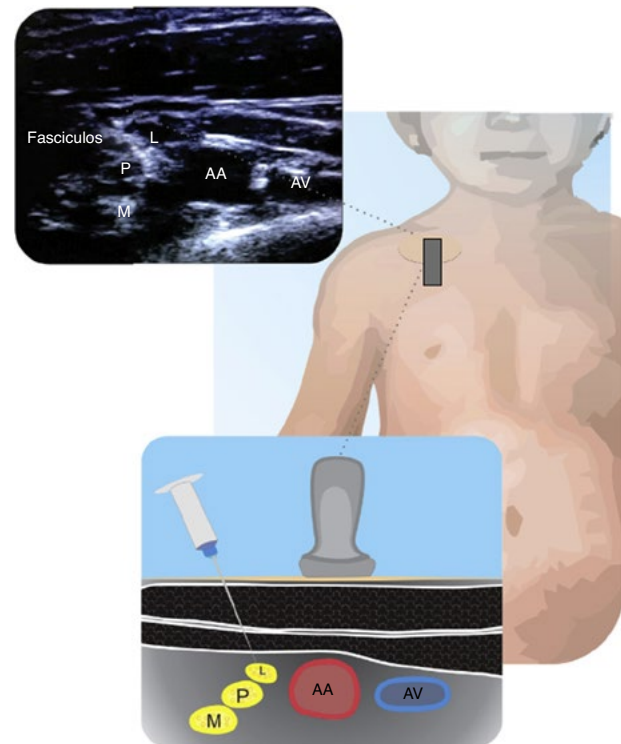


Fig. 3 – Infraclavicular block. Illustrates the neurovascular bundles (L: lateral; P: posterior and M: medial) and their relationship to the axillary artery (AA) and the axillary vein (AV). Fuente: Authors.

efficacy²¹. Fig. 2 shows the relationship of the brachial plexus with the subclavian artery, the pleura and the first rib.

Infraclavicular

This is an alternative to the previously described approach and it is recommended when the ultrasound visualization of the infraclavicular is better than the supraclavicular approach. Both outside and inside the plane techniques yield adequate results²⁶. Fig. 3 shows the neurovascular bundles and their relationship to the axillary artery.

Axillary

Although this is a popular approach in adults, periclavicular approaches are preferred in children because these avoid the abduction of an injured upper extremity and also because in many cases the visualization of very superficial structures is difficult. The axillary approach is indicated for forearm and hand surgical procedures and the recommendation is to use inside the plane techniques²¹. Fig. 4 illustrates the position of the axillary artery relative to the nerves.

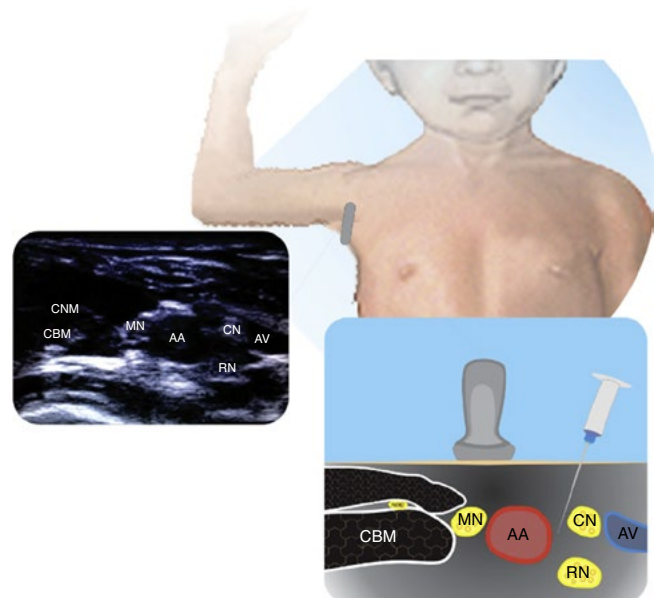


Fig. 4 – Axillary block. Illustrates the axillary artery (AA) relative to the cutaneous nerve muscles (CNM), medial nerve (MN), cubital nerve (CN) and the radial nerve (RN); coracobrachialis muscle (CBM); axillary vein (AV). Fuente: Authors.

Lower limb blocks

Most lower limb procedures may benefit from regional techniques, although they may frequently require at least two nerve blocks²⁴. The following are the most frequent approaches using ultrasound guidance.

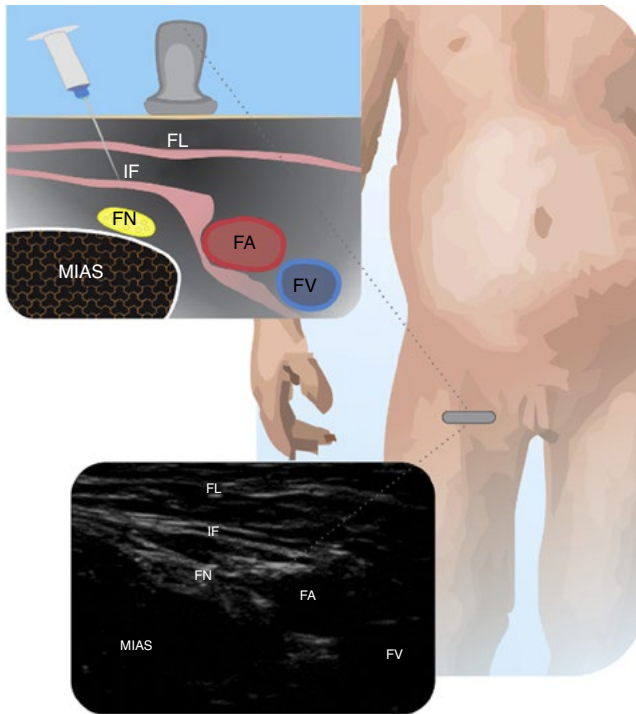


Fig. 5 – Femoral nerve. Depicts the femoral nerve (FN) relative to the femoral artery (FA) and the femoral vein (FV); fascia lata (FL); iliac fascia (IF); iliopsoas muscle (MIAS).
Fuente: Authors.

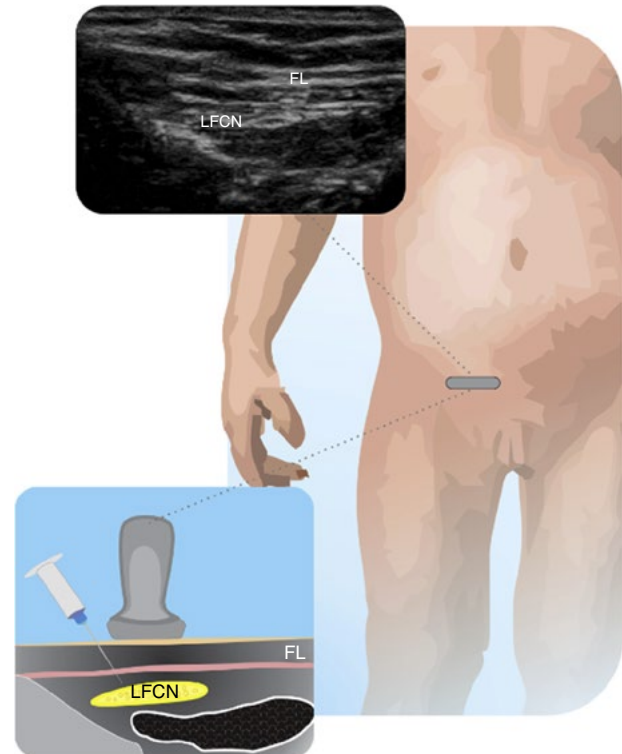


Fig. 6 – Lateral femoral cutaneous nerve (LFCN). Illustrates the LFCN and anatomical landmarks. Fascia lata (FL).
Fuente: Authors.

Femoral nerve

This approach is useful in femur fractures, in arthroscopy and for the reconstruction of knee ligaments, inter alia²⁷. It is done by placing the probe on the femoral fold and localizing the femoral artery (FA). The recommendation is to insert the needle inside the plane and move from lateral to posteromedial²⁴. Parents should be advised that the child should not stand up until the complete resolution of the block. Fig. 5 depicts the femoral nerve and its anatomical relationships.

Lateral femoral cutaneous nerve

This approach is helpful for grafting or taking biopsies of the innervated zone, for preventing tourniquet pain and to complement knee surgery²⁴. The femoral nerve and vessels should be located and the iliac fascia must be traced towards the anterior superior iliac spine, until a round hyperechogenic structure is identified. Either out-of-plane or in-plane approaches may be used²⁴. Fig. 6 shows the LFCN and its anatomical relationships.

Obturator nerve

Recommended to complement femoral block analgesia in knee surgery. The number of literature reports on pediatric ON block is limited²⁸. To perform the ON block, the FA is identified in the inguinal fold, and the probe advances medially toward the pubic symphysis until the three adductor muscles are identified. The two branches of the ON are superficial and

deep to the short adductor, and the approach may be either in-plane or out-of-plane²⁴. Fig. 7 illustrates the Obturator Nerve relative to the adductor muscles.

Saphenous nerve

It can be used to complement the sciatic nerve block for foot and ankle surgeries. Selective SN block avoids weakening the femoral quadriceps. For the subsartorial approach, the child is placed with a slight external rotation of the hip and knee flexion. The FA is localized medially to the muscle. Advance caudally until the separation of the artery and the nerve. The needle enters in an anteroposterior direction, between the vastus medialis and the sartorium^{29,30}. Fig. 8 shows the SN in relationship to the FA and the sartorium muscle in the distal third of the muscle.

Popliteal sciatic nerve block

This approach is useful for surgical procedures of the tibia, the fibula, the posterior aspect of the knee, ankle and foot²⁴. The spread of the anesthetic agent around the nerve is an important parameter for the rapid block onset³¹. Both in-plane and out-of-plane approaches may be used²⁴. Fig. 9 illustrates the PSN with its two components and the position versus the popliteal vessels.

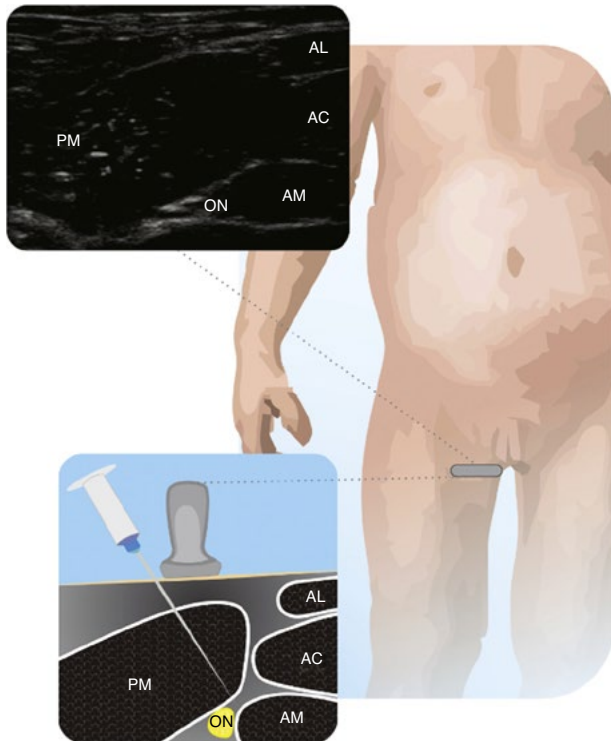


Fig. 7 – Obturator nerve (ON). Illustrates the ON prior to separating into the adductor muscles. Adductor longus (AL); adductor brevis (AC); adductor magnum (AM); pectineus muscle (PM).
Fuente: Authors.

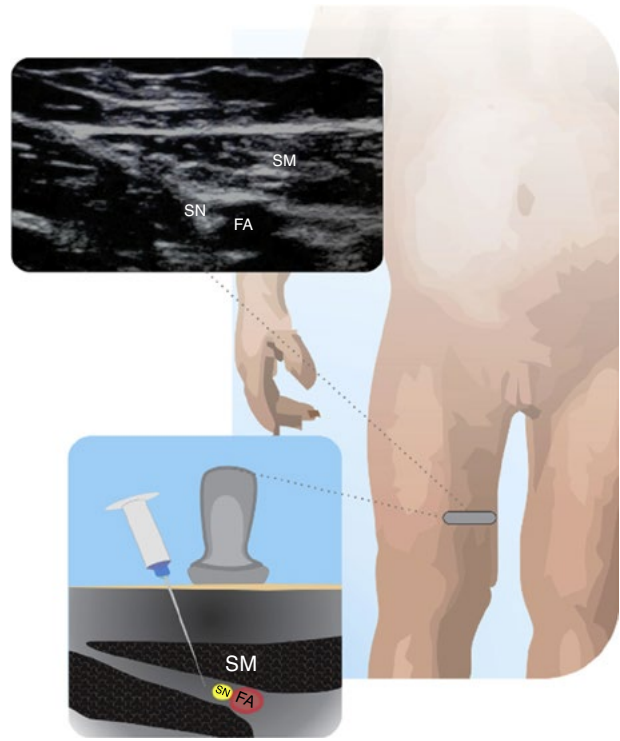

Fig. 8 – Saphenous nerve (SN). Illustrates the SN relative to the femoral artery (FA) and the sartorius muscle (SM) in the distal third of the thigh.
Fuente: Authors.

Abdominal wall blocks

Although the pediatric neuraxial blocks have been used as analgesic techniques with excellent results, these blocks have undesirable side effects. Peripheral blocks may avoid these side effects and provide similar analgesia³². The use of ultrasound to guide these blocks has led to higher efficacy than the techniques based on anatomical landmarks³².

These include:

Transverse abdominis plane block

This block was described by Rafi³³ as a blind technique, and although it was used for many years, US has further expanded its use.

The abdominal wall is innervated by the anterior branches of T6 to L1, running between the internal oblique and transverse muscles of the abdomen^{34,35}. Figs. 10.1 and 10.2 illustrate the technique for placing the transducer and visualizing the muscle groups.

The indications for this particular block are abdominal wall surgeries, urology, and any patient conditions that are a contraindication for neuraxial blocks. The TAPB has a longer effect and improved quality of analgesia than infiltration of the surgical wound in children between 2 and 8 years old³⁶. Being an analgesic block, the use of long-lasting local anesthetic agents at low concentrations is recommended.

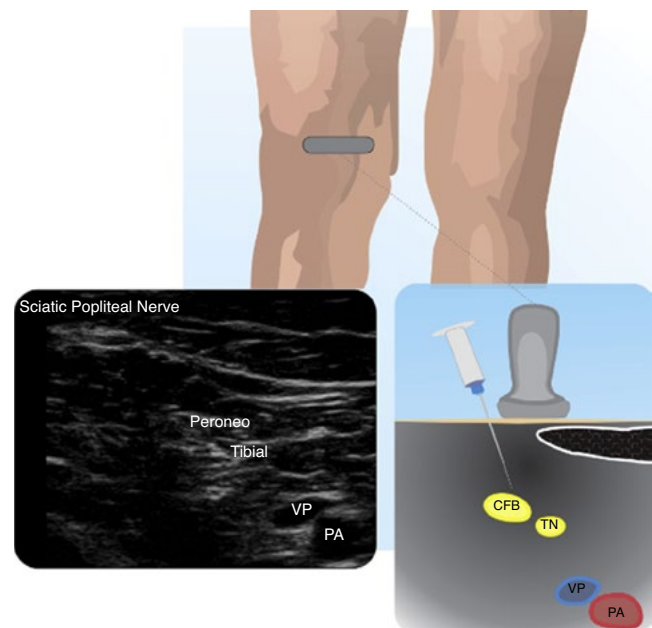


Fig. 9 – Sciatic popliteal nerve (SPN). Depicts the SPN at the insertion of its two components: tibial nerve (TN) and common fibular nerve (CFB). popliteal artery (PA).
Fuente: Authors.

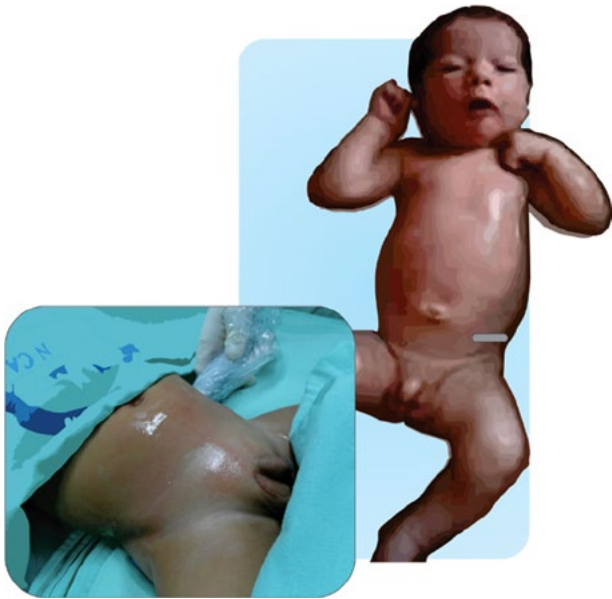

Fig. 10.1 – Placement of an US probe for a transverse abdominis plane block. High frequency transducer at the level of the subcostal mid axillary line, above the iliac crest. Fuente: Authors.

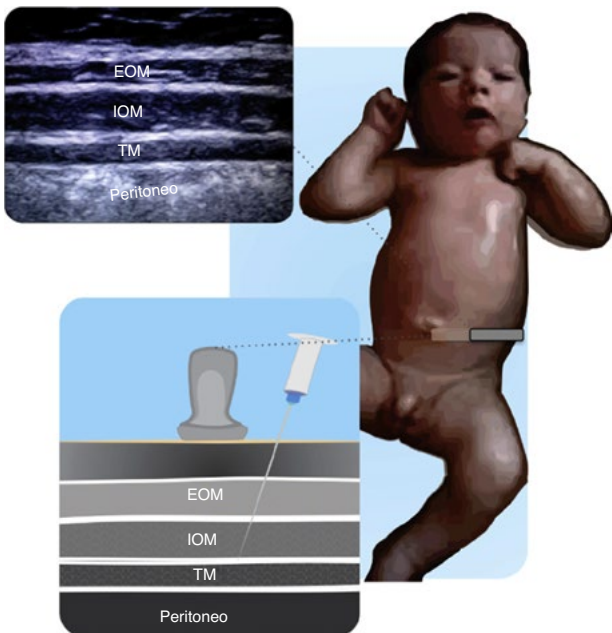


Fig. 10.2 – Anatomical structures of a transverse abdominis plane block (TAPB), transverse muscle (TM), internal oblique muscle (IO), and external oblique muscle (EOM). The local anesthetic agent deposits between the TM and the IOM. Fuente: Authors.

Ilioinguinal and iliohypogastric block (II-IH)

Used for procedures in the inguinal region and for urological surgeries, this approach was shown to be equivalent to the caudal block³², and some reports claim longer analgesia and less frequent use of rescue analgesics³⁷.

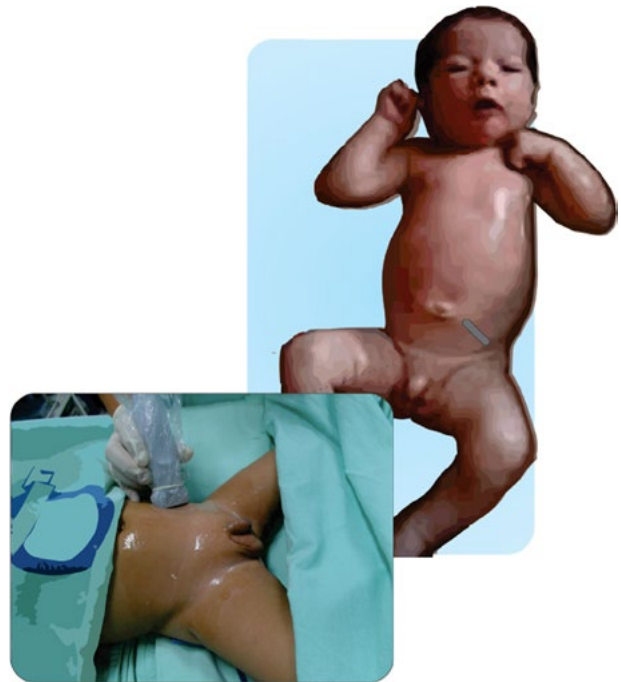

Fig. 11.1 – Placement technique of the US probe for ilio inguinal and ilio hypogastric (II-IH) nerve blocks over the anterosuperior iliac spine pointing toward the umbilicus. Fuente: Authors.

This block was performed for many years using anatomical landmarks, but some trials report the correct placement of the LA in only 14% of the cases³⁸, in addition to other complications such as intestinal puncture³⁹.

Figs. 11.1 and 11.2 illustrate the technique for placing the probe, enabling the visualization of the iliac crest, the Ilioinguinal and Iliohypogastric nerves, the muscle groups and the peritoneum. The objective of the block is to reach the fascia separating the internal from the transverse oblique⁴⁰.

Rectus sheath block

The use of the rectus sheath block in children was originally described by Ferguson et al⁴¹. and Courreges et al⁴². for umbilical hernia repair, pyloric-myotomies and abdominal mid-line incisions. The nerve roots run between the posterior sheath formed by the fascia of the internal and transverse oblique muscles. US has expanded the use of this block because it is easy and effective. Figs. 12.1 and 12.2 depict the technique for placing the transducer and the block target structures.

The current role of neurostimulation

NE was introduced in the 1960s as an alternative to the paresthesia technique, objectively localizing the nerve and allowing for the injection of the agent as close as possible avoiding any injuries⁴³. Following the introduction of ultrasound, the technique has been compared against other existing tools in an attempt to emphasize its advantages in terms of safety and the prevention of complications; however, since the occurrence of

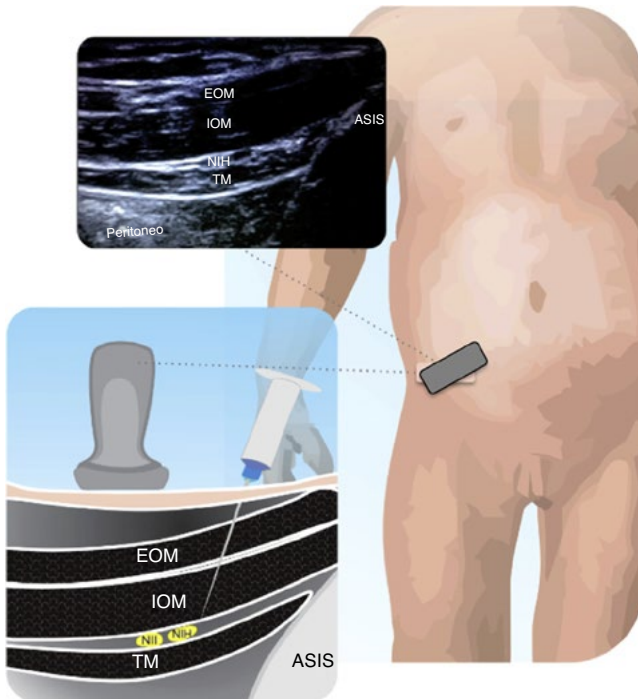

Fig. 11.2 – Anatomical structures identified during an ilio inguinal and ilio hypogastric (II-IH) nerve block. Transverse muscle (TM), Internal oblique (IO) and external oblique (EO); anterosuperior iliac spine (ASIS). The local anesthetic agent deposits between the TM and the IOM.
Fuente: Authors.

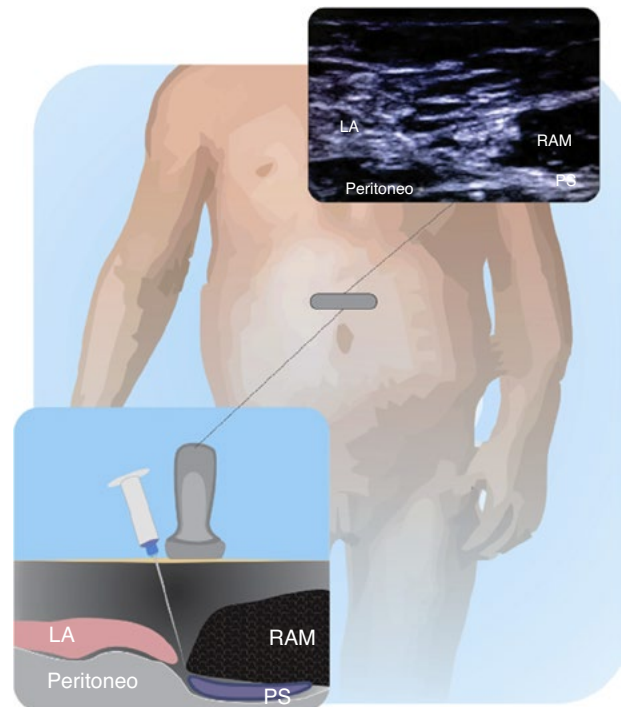

Fig. 12.2 – Structures identified when performing a rectus sheath block. The posterior sheath (PS) is the target site to deposit the local anesthetic agent. Rectus abdominis muscle (RAM); linea alba (LA).
Fuente: Authors.

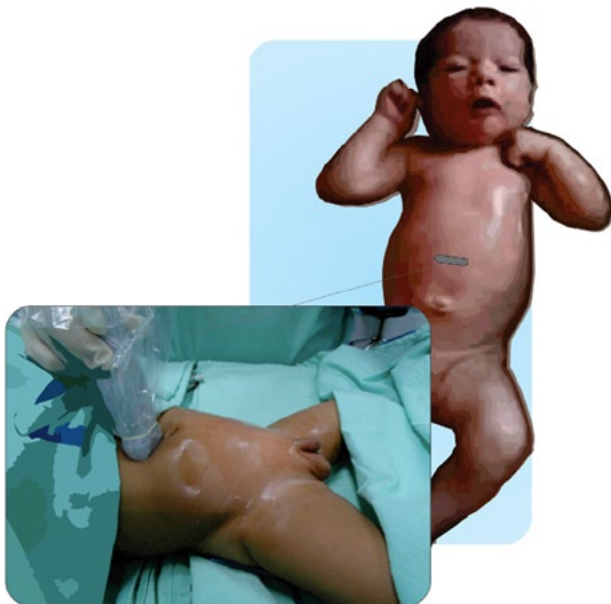

Fig. 12.1 – Technique for placing the transducer for a rectus sheath block.
Fuente: Authors.

adverse events is rare in Regional Anesthesia, no significant differences have been identified^{44,45}.

One of the current advantages of NE is the combined use with ultrasonography to prevent intraneural injection. Neurostimulation with less than 0.2 mA is indicative of intraneural

localization. This explains why using both techniques is useful and may prevent complications⁴⁶.

NE may be used to check the position of the needle and the catheter into the epidural space in 80–100% of the cases, particularly if the procedure is performed with the patient anesthetized or sedated⁴⁷.

New local anesthetics

Levobupivacaine and ropivacaine have an improved safety profile as compared against racemic bupivacaine and should be used as a routine for central and peripheral blocks^{1,15,48}. Both agents are pure enantiomers S(-) with an improved profile and adequate sensory block, in addition to lower risk of cardiac fiber block. Local Anesthetics bind to plasma proteins, particularly to the acid alpha-1 glycoprotein that has a low concentration at birth and increases during the first year of life. Cytochrome CYP1A2 that metabolizes lidocaine and ropivacaine is immature until age 4–7⁴⁹. Hence, neonates and infants are prone to LA toxicity because of the increased free fraction, reduced clearance and increased susceptibility to cardiac toxicity.

The recommended doses vary depending on the block; however, the average dose is 2 mg/kg for ropivacaine and 2.5 mg/kg for levobupivacaine^{4,50}. Dosing for continuous infusion in epidural and perineural blocks ranges from 0.2 to 0.6 mg/kg/h in both cases⁵⁰.

Conclusion

The renewed interest on Pediatric Regional Anesthesia is due to its adequate pain control and the use of ultrasound that enables the visualization of the anatomical structures, the needle and the spread of the local anesthetic agent, all of which translates into an improved safety profile and less complications. Administering blocks to anesthetized or sedated children is safer than in patients who are awake. Ultrasound guidance is not absolutely risk-free and therefore, it is recommended to include training in ultrasound guided regional anesthesia as part of the standard curricula, to develop skills for everyday clinical practice.

Conflict of interest

The authors have no conflict of interest to declare.

Funding

None.

REFERENCES

- Ecoffey C. Pediatric regional anesthesia – update. *Curr Opin Anaesthesiol.* 2007;20:232–5.
- Rubin K, Sullivan D, Sadhasivam S. Are peripheral and neuraxial blocks with ultrasound guidance more effective and safe in children? *Paediatr Anaesth.* 2009;19:92–6.
- Suresh S, Schaldenbrand K, Wallis B, De Oliveira GS Jr. Regional anaesthesia to improve pain outcomes in paediatric surgical patients: a qualitative systematic review of randomized controlled trials. *Br J Anaesth.* 2014;113:375–90.
- Ivani G, Ferrante FM. The American Society of Regional Anesthesia and Pain Medicine and the European Society of Regional Anaesthesia and Pain Therapy Joint Committee recommendations for education and training in ultrasound guided regional anesthesia: why do we need these guidelines? *Reg Anesth Pain Med.* 2009;34:8–9.
- Bosenberg A. Benefits of feional anesthesia in children. *Pediatr Anesth.* 2012;22:10–8.
- Ivani G, Mossetti V. Pediatric regional anesthesia. *Minerva Anesthesiol.* 2009;75:577–83.
- Bier A. Versuche uber Cocainisierung des Ruckenmarkes. *Deutsches Zeitschrift für Chirurgie.* 1899;51:361–9.
- Labat G. Regional anesthesia: its techniques and clinical application. Philadelphia: W.B. Saunders; 1922.
- Brown TC. History of pediatric regional anesthesia. *Paediatr Anaesth.* 2012;22:3–9.
- Krane EJ, Dalens BJ, Murat I, Murrell D. The safety of epidurals placed during general anesthesia. *Reg Anesth Pain Med.* 1998;23:433–8.
- Bosenberg A, Ivani G. Editorial: regional anesthesia: children are different. *Paediatr Anaesth.* 1998;8:447–50.
- Ivani G, Conio A, Papurel G, Ciliberto F, Vitale P. 1000 consecutive blocks in a children's hospital; how to manage them safely. *Reg Anesth Pain Med.* 2001;26:93–4.
- Breschan C, Jost R, Krumpholz R, Schaumberger F, Stettner H, Marhofer P, et al. A prospective study comparing the analgesic efficacy of levobupivacaine, ropivacaine and bupivacaine in pediatric patients undergoing caudal blockade. *Paediatr Anaesth.* 2005;15:301–6.
- Denny NM, Editorial I. Location, location, location! Ultrasound imaging in regional anaesthesia. *Br J Anaesth.* 2005;94:1–3.
- Moriarty A. Pediatric epidural analgesia (PEA). *Paediatr Anaesth.* 2012;22:51–5.
- Jöhr M. Practical pediatric regional anesthesia. *Curr Opin Anaesthesiol.* 2013;26:327–32.
- Ivani G, Mossetti V. Continuous central and perineural infusions for postoperative pain control in children. *Curr Opin Anaesthesiol.* 2010;23:637–42.
- Kokki H. Spinal blocks. *Paediatr Anaesth.* 2012;22:56–64.
- Tobias JD. Spinal anaesthesia in infants and children. *Paediatr Anaesth.* 2000;10:5–16.
- Kachko L, Simhi E, Tzeitlin E, Efrat R, Tarabikini E, Peled E, et al. Spinal anesthesia in neonates and infants – a single-center experience of 505 cases. *Paediatr Anaesth.* 2007;17:647–53.
- Marhofer P, Willschke H, Kettner SC. Ultrasound-guided upper extremity blocks – tips and tricks to improve the clinical practice. *Paediatr Anaesth.* 2012;22:65–71.
- Kretz FJ, Krier C. A child with a full stomach has to be anesthetized. *Anesthesiol Intensivmed Notfallmed Schmerzther.* 2002;37:514–9.
- Tobias JD, Hoernschemeyer DG. Near infrared spectroscopy identifies compartment syndrome in an infant. *J Pediatr Orthop.* 2007;27:311–3.
- Flack S, Anderson C. Ultrasound guided lower extremity blocks. *Paediatr Anaesth.* 2012;22:72–80.
- Fredrickson MJ. Ultrasound-assisted interscalene catheter placement in a child. *Anaesth Intensive Care.* 2007;35:807–8.
- Marhofer P, Sitzwohl C, Greher M, Kapral S. Ultrasound guidance for infraclavicular brachial plexus anaesthesia in children. *Anaesthesia.* 2004;59:642–6.
- Suresh S, Frederickson M. Peripheral nerve blocks in children. In: Hadzic A, editor. *Textbook of regional anesthesia and pain management.* New York: McGraw Hill; 2007. p. 753–78.
- Anagnostopoulou S, Kostopanagiotou G, Paraskeuopoulou T, Alevizou A, Saranteas T. Obturator nerve block: from anatomy to ultrasound guidance. *Anesth Analg.* 2008;106:350.
- Tsui B, Ozelsel T. Ultrasound-guided trans sartorial periferomral artery approach for saphenous nerve block. *Reg Anesth Pain Med.* 2009;34:177–8.
- Horn JL, Pitsch T, Salinas F, Benninger B. Anatomic basis to the ultrasound-guided approach for saphenous nerve blockade. *Reg Anesth Pain Med.* 2009;34:486–9.
- Morau D, Levy F, Bringuier S, Biboulet P, Choquet O, Kassim M, et al. Ultrasound guided evaluation of the local anesthetic spread parameters required for a rapid surgical popliteal sciatic nerve block. *Reg Anesth Pain Med.* 2010;35:559–64.
- Oliver JA, Oliver LA. Beyond the caudal: truncal blocks an alternative option for analgesia in pediatric surgical patients. *Curr Opin Anaesthesiol.* 2013;26:644–51.
- Rafi AN. Abdominal field block: a new approach via the lumbar triangle. *Anaesthesia.* 2001;56:1024–30.
- O'Donnell BD, McDonnell JG, McShane AJ. The transversus abdominis plane (TAP) block in open retropubic prostatectomy. *Reg Anesth Pain Med.* 2006;31:91.
- McDonnell JG, O'Donnell, Curley G, Haffernan A, Power C, Laffey JG. The analgesic efficacy of transversus abdominis Plane Block after abdominal surgery: a prospective randomized controlled trial. *Anesth Analg.* 2007;104:193–7.
- Sahin L, Sahin M, Gul R, Saricicek V, Isikay N. Ultrasound-guided transversus abdominis plane block in children: a randomized comparison with wound infiltration. *Eur J Anaesthesiol.* 2013;30:409–14.
- Abualhassan AA. Ultrasound-guided ilioinguinal/liliohipogastric nerve blocks versus caudal block

- for postoperative analgesia in children undergoing unilateral groin surgery. *Saudi J Anaesth.* 2012;6:367-72.
38. Weintraud M, Marhofer P, Bösenberg A, Kapral S, Willschke H, Felfernig M, et al. Ilioinguinal/iliohypogastric blocks in children: where do we administer the local anesthetic without direct visualization? *Anesth Analg.* 2008;106:89-93.
39. Amory C, Mariscal A, Guyot E, Chauvet P, Leon A, Poli-Merol ML. Is ilioinguinal/iliohypogastric nerve block always totally safe in children? *Paediatr Anaesth.* 2003;13:164-6.
40. Erez I, Buchumensky V, Shenkman Z, Lazar L, Freud E. Quadriceps paresis in pediatric groin surgery. *Pediatr Surg Int.* 2002;18:157-8.
41. Ferguson S, Thomas V, Lewis I. The rectus sheath block in paediatric anaesthesia: new indications for an old technique? *Paediatr Anaesth.* 1996;6:463-6.
42. Courreges P, Poddevin F, Lecoutre D. Para-umbilical block: a new concept for regional anaesthesia in children. *Paediatr Anaesth.* 1997;7:211-4.
43. Greenblatt GM, Denson JS. Needle nerve stimulator/locator: nerve blocks with a new instrument for locating nerves. *Anesth Analg.* 1962;41:599-602.
44. Abrahams MS, Aziz MF, Fu RF, Horn JL. Ultrasound guidance compared with electrical neurostimulation for peripheral nerve block: a systematic review and meta-analysis of randomized controlled trials. *Br J Anaesth.* 2009;102:408-17.
45. Neal JM, Brull R, Chan VW, Grant SA, Horn JL, Liu SS, et al. The ASRA evidence-based medicine assessment of ultrasound-guided regional anesthesia and pain medicine: executive summary. *Reg Anesth Pain Med.* 2010;35:S1-9.
46. Dillane D, Tsui BC. Is there still a place for the use of nerve stimulation? *Paediatr Anaesth.* 2012;22:102-8.
47. Tsui BC, Gupta S, Finucane B. Confirmation of epidural catheter placement using nerve stimulation. *Can J Anaesth.* 1998;45:640-4.
48. Imbelloni LE, Vieira EM, Sporni F, Guizellini RH, Tolentino AP. Spinal anesthesia in children with isobaric local anesthetics: report on 307 patients under 13 years of age. *Paediatr Anaesth.* 2006;16:43-8.
49. Mazoit JX. Local anesthetics and their adjuncts. *Paediatr Anaesth.* 2012;22:31-8.
50. De Negri P, Ivani G, Tirri T, Del Piano AC. New local anesthetics for pediatric anesthesia. *Curr Opin Anaesthesiol.* 2005;18:289-92.