



Colombian Journal of Anesthesiology

Revista Colombiana de Anestesiología

www.revcolanest.com.co

OPEN

Wolters Kluwer

Impending paradoxical embolism, patent foramen ovale and pregnancy. Case report

Embolismo paradójico inminente, foramen ovale permeable y embarazo. Reporte de caso

Carlos Eduardo Laverde-Sabogal^{a,b}, July Vianneth Torres-González^c

^a Intensive Care Unit, Hospital Universitario San Ignacio, Bogotá, Colombia

^b Department of Internal Medicine, School of Medicine, Pontificia Universidad Javeriana, Bogotá, Colombia

^c Pulmonology Unit, Department of Internal Medicine, School of Medicine, Pontificia Universidad Javeriana, Bogotá, Colombia

Keywords: Foramen Ovale, Patent, Embolism, Paradoxical, Pulmonary Embolism, Pregnant Women, Thrombosis

Palabras clave: Forámen Oval Permeable, Embolia paradójica, Embolia Pulmonar, Mujeres embarazadas, Trombosis

Abstract

Objectives: A clinical case and an updated literature review on impending paradoxical embolism are discussed, describing their incidence, etiology, and pathophysiology.

Materials and methods: Revised by the Service of Clinical Ethics of our hospital, this is a case of a 37-year-old woman with 27 weeks of gestation who consulted because of progressive apnea leading to functional class IV/IV; her ICU management and outcomes are discussed. The bibliography used were searched from PubMed, SciELO, and Bireme.

Results: Impending paradoxical embolism is a rare condition and few cases have been reported in Ibero-America. The condition has a significant impact on a young and otherwise healthy population, with high morbidity and mortality for both the baby and the mother. An association with several cardiovascular and neurological conditions has been suggested.

Conclusions: The association between patent foramen ovale and impending paradoxical embolism is rare. Its occurrence during pregnancy is even more insignificant. The existing treatment evidence to date is weak, apparently in favor of

surgical management rather than thrombolysis and anticoagulation alone, further avoiding the recurrence of the disease.

Resumen

Objetivos: Presentamos un caso clínico y revisión actualizada de la literatura sobre el embolismo paradójico inminente, describiendo su incidencia, etiología y fisiopatología.

Materiales y Métodos: Revisado por el servicio de Ética Clínica denuetrohospital, se presenta el caso de una mujer de 37 años con 27 semanas de embarazo quien consulto por disnea progresiva hasta clase funcional IV/IV, sumanejo en UCI y desenlace. Las bases bibliográficas fueron Pub Med, SciELO y Bireme.

Resultados: El embolismo paradójico inminente es una patología rara, con pocos casos reportados en Iberoamérica. Presenta un importante impacto en una población joven y sana, con una alta morbimortalidad en el binomio madre-hijo. Se propuso una relación con diversas patologías cardiovasculares y neurológicas.

Conclusiones: La asociación entre foramen ovale permeable, embolismo paradójico inminente es poco frecuente. Su presen-

How to cite this article: Laverde-Sabogal CE, Torres-González JV. Impending paradoxical embolism, patent foramen ovale and pregnancy. Case report. Rev Colomb Anestesiología. 2018;46:79-83.

Read the Spanish version of this article at: <http://links.lww.com/RCA/A1>.

Copyright © 2018 Sociedad Colombiana de Anestesiología y Reanimación (S.C.A.R.E.). Published by Wolters Kluwer. This is an open access article under the CC BY-NC-ND license (<http://creativecommons.org/licenses/by-nc-nd/4.0/>).

Correspondence: Cra. 7 No. 40-62 Hospital Universitario San Ignacio, Bogotá, Colombia. E-mail: celaverde@husi.org.co

Rev Colomb Anestesiología (2018) 46:1

<http://dx.doi.org/10.1097/CJ9.0000000000000015>

tación durante el embarazo es aun menor. La evidencia existente a la fecha sobre el tratamiento es débil, parece favorecer el manejo quirúrgico sobre la trombolisis y anticoagulación sola, adicionalmente se evita su recurrencia.

Introduction

In 1877, Cohnheim described and defined paradoxical embolism as the passage of a venous thrombus into the systemic circulation via a cardiac right to left shunt, through a patent ductus, interatrial, and/or interventricular communication.¹ Straddling thrombi in the foramen ovale were originally described by Nellessen in 1985, with a risk of impending paradoxical embolism and associated with several conditions including embolic stroke, platypnea-orthodeoxia syndrome, divers gas embolism, and migraine.^{1,2}

During pregnancy, a thromboembolic physiological status develops, influenced by increased activity of coagulation factors VII, X, and VIII, in contrast with decreased fibrinolytic factors activity, mainly protein S.³

Clinical case

A 37-year-old patient with 27 weeks of pregnancy, works as a road technician, born in Bogotá (Colombia), mestizo race, weighs 65 kg and is 1.60 m tall, was discussed. Her only medical history is childhood hepatitis A (ObGy profile: G3P2C0V2) and uneventful previous term pregnancies with vaginal delivery. The patient came to the clinic because of a 15-day course of progressive dyspnea up to functional class IV/IV. Her physical examination evidenced tachycardia and pansystolic murmur grade VI/VI, radiating to baseline foci with S2 reinforcement. Positive fetal movements with 140 beats/min fetal heart rate. Evidence of equimosis and asymmetry of the lower left limb.

In the ER, suspicion of pulmonary thromboembolism (PTE) was confirmed with transthoracic ultrasound; the foramen ovale evidenced cylindrical echodensity 60 mm

long and 14 mm of diameter actively crossing the foramen ovale (straddling thrombus) with at least 30 mm of the thrombus localized in the left atrium (Table 1 and Fig. 1). Additionally, the left lower limb was asymmetric and deep venous thrombosis (DVT) of the left popliteal vein was confirmed with Doppler. Cardiovascular surgery performed a thrombectomy and closure of the foramen ovale with a surgical time of 180 minutes (min), under extracorporeal circulation of 71 and 47 min clamp. Blood cardioplegia. Invasive hemodynamic monitoring and pulmonary artery catheter. Bleeding 500 mL. Temperature 34°C. Nitric oxide was initiated due to supra-systemic pulmonary hypertension (Table 2). The surgical findings included a large 50 mm long × 10 mm wide thrombus; 80% of the thrombus was lodged in the left atrium, anchored to the septum and across the foramen ovale (Fig. 2). Continuous Doppler was used for fetal monitoring. At the time of admission to the Intensive Care Unity (ICU), the patient was under assisted ventilation, vasopressors, inotropic agent, and inodilation. The fetal heart rate was 120 bpm, capillary filling over 4 seconds. Forty-eight hours later, the ultrasound examination confirmed the absence of fetal heart rate. After 18 hours, during delivery the patient experienced 2,000 mL of blood loss, the red code was activated and managed with crystalloids, 4 Red Blood Cells (RBC) units were transfused, and a Bakri uterine balloon was placed for uterine tamponade; additionally, rectal oxytocin, methyl-ergonovine, and misoprostol 400 mg were administered. The uterine balloon was removed after 48 hours. The hemodynamics and arterial blood gases evolved satisfactorily to enable the removal of the multisystem support (Table 2). The invasive ventilation strategy developed successfully for 5 days, using a controlled assisted ventilation approach, positive end expiratory pressure of 8, with high-inspired oxygen fractions (100%) during the first 24 hours, using nitric oxide.

The cardiac failure management was optimized reducing the ventricular response with carvedilol, cardioselective betablocker, enalapril, angiotensin-converting

Table 1. Transthoracic echocardiography

Date	LVEF	PSBP	Description
June 3	60%	70 mmHg	Severe diastolic dysfunction secondary to right ventricular pressure overload Severe dilatation of the right cavities, dilated tricuspid ring 36 mm. Severe tricuspid regurgitation Paradoxical movement of the IV septum Pulmonary artery dilatation Foramen ovale with cylindrical echogenicity 60 mm long × 14 mm wide, actively crossing the foramen ovale with at least 30 mm of the structure inside the left atrium Minimal pericardial effusion
June 7	60%	40 mmHg	Severely dilated right cavities with signs of RV systolic dysfunction Severe tricuspid regurgitation Rectified interventricular septum and with paradoxical movement due to volume and pressure overload. Signs of type 1 diastolic dysfunction. Mildly dilated left atrium Normal left valves

LV=left ventricle, RV=right ventricle, LVEF=LV ejection fraction, PSBP=pulmonary systolic blood pressure, IV=interventricular.

Source: Authors.

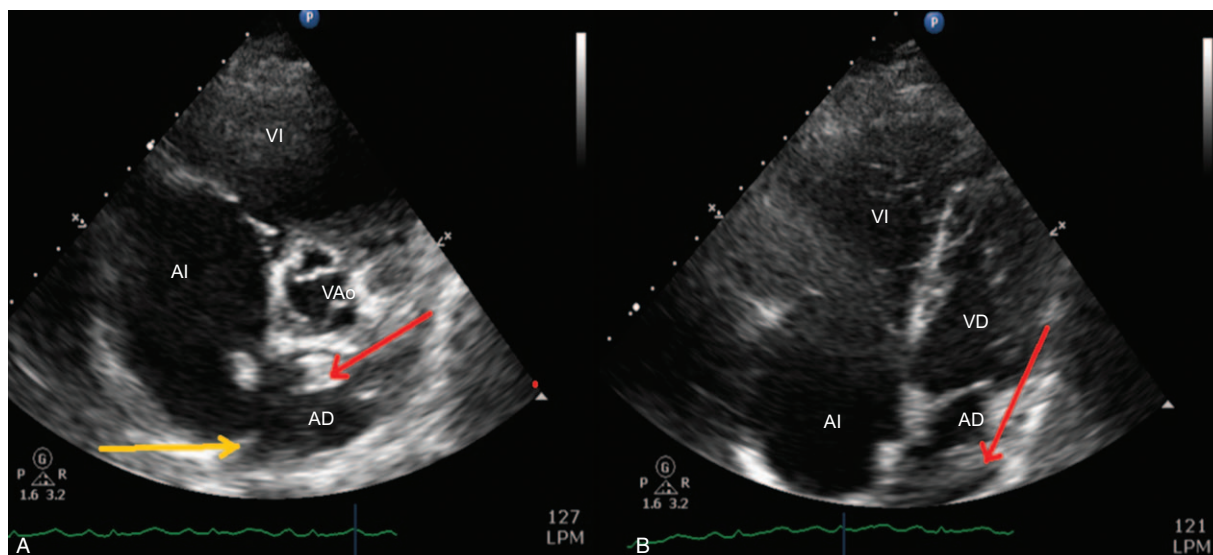


Figure 1. Transthoracic ultrasound. (A) Parasternal view. (B) Four chamber view. Right atrium (AD), left atrium (AI), right ventricle (VD), left ventricle (VI), aortic valve (VAo), patent foramen ovale (yellow arrow), thrombus (red arrow). Source: Authors.

enzyme inhibitor, and spironolactone, with a view to blocking the renin–angiotensin–aldosterone axis (neurohumoral block). Anticoagulation with low molecular weight heparin. Subsequently, the patient developed congestive and erythematous breasts, temperature of 39°C with no leukocytosis and was interpreted as mastitis and treated with meropenem. Positive blood cultures for *Citrobacter freundii* (cyclic AMP inducer). The patient was discharged after favorable clinical evolution.

Discussion

The foramen ovale is an interatrial communication during the fetal period allowing for the passage of oxygenated blood from the placenta into the systemic circulation. A patent foramen ovale persists in 25% of the adult population.² Impending paradoxical embolism is a very rare condition. Few case reports or observational studies

can be found in the last 5 years, and the only systematic review available in the literature includes 174 patients.^{4–7} We found a total of 6 cases in Ibero-America.^{8–13} The occurrence of patent foramen ovale during pregnancy and puerperium is very rare.⁸ The differential diagnosis includes vegetations and myxomas.² Clinically, the condition presents with dyspnea, chest pain, and syncope. Paradoxical embolism is rare, with a 91% prevalence of pulmonary and 55% systemic involvement.^{2,4} Five factors must be present for the condition to develop: (1) an embolic source (DVT and/or PTE); (2) abnormal right and left circulation communication; (3) an angiographic or pathological evidence of embolism; (4) a pressure change that favors the right to left shunt; and (5) the arterial embolism shall not originate in the left circulation of the heart. The previously listed conditions represent a final diagnosis and comprise the triad described by Dahl Ibersen in 1930, that is, an embolic source, the nature of

Table 2. Hemodynamic profile, arterial–venous blood gas and vasopressor support

Date	ABP, mmHg	HR, bpm	SO ₂ %	SPBP/DPBP (MPBP), mmHg	PWP, mmHg	CVP, cm H ₂ O	pH	PO ₂ , mmHg	PCO ₂ , mmHg	HCO ₃ , mmol/L	BE, mmol/L	Lactate	PaO ₂ /FIO ₂	SVO ₂	NA, µg/kg/min	VA, UI/h	M, µg/kg/min	NO, ppm	NTG, µg/kg/min
June 3	98/79	121	90	—	—	—	7.46	55	28	72	−3.9	ND	229	ND	-	-	-	-	-
June 4	90/62	120	88	105/58 (70)	30	18	7.28	67	42	19.7	−7	5.4	101	50%	0.9	5	0.5	40	0,125
June 6	97/87	114	94	61/36 (44)	25	12	7.33	101	37	19	−6.9	3.3	114	58%	0.5	2	0.5	40	0,125
June 7	9/62	113	89	40/24 (29)	22	19	7.38	72	35	20.7	−4.4	1.9	228	49%	0.2	2	0.7	30	-
June 8	120/77	100	93	35/22 (26)	14	13	7.38	80	42	24.8	−0.3	1	285	65%	0.08	-	0.5	25	-

BP=blood pressure, HR=heart rate, PVC=central venous pressure, SO₂=arterial oxygen saturation, SABP=systolic arterial blood pressure, DPBP=diastolic pulmonary blood pressure, MPBP=mean pulmonary blood pressure, PWP=pulmonary wedge pressure, BE=Base excess, SVO₂=venous oxygen saturation) noradrenaline=NA, vasopressin=VA, milrinone=M, Nitroglycerin=NTG, nitric oxide=NO, parts per million=ppm, NA=not available Source: Authors.

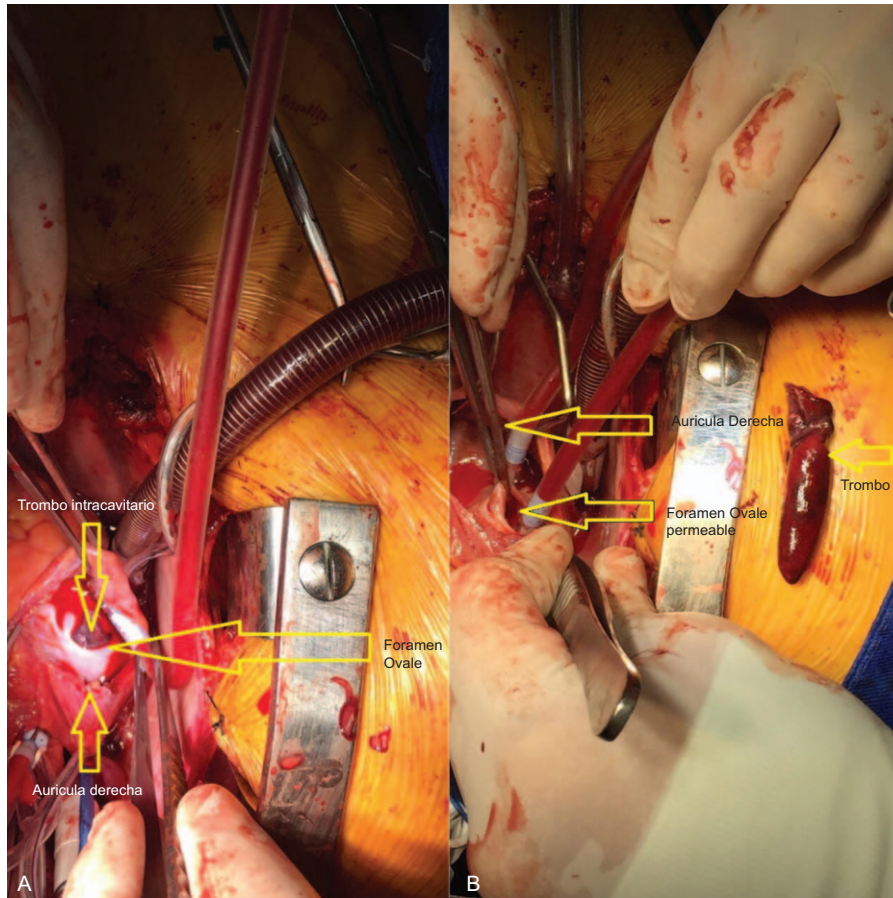


Figure 2. Intracavitary thrombus. (A) The foramen ovale is depicted with the intracavitary thrombus (right atrial view). (B) Depiction of he intracavitary thrombus and the foramen ovale.
Source: Authors.

the source has to be venous, and the presence of shunt.^{9,14} The mortality rate is 18%, and 66% of the patients die in the first 24 hours.⁴ The main causes of death are cardiogenic shock and/or right ventricular failure, followed by stroke. DVT was the source of the embolism in 22% of the cases, with at least 1 risk factor identified in 35% of the patients, including primary hypercoagulability, malignancy, recent postoperative period, immobility of the patient due to fractures, inadequate antithrombotic prophylaxis. The diagnosis was done via transthoracic and transesophageal echocardiography, computerized tomography, magnetic resonance, in 57%, 40%, 2.9%, and 0.6%, respectively.¹⁵

With regards to therapy, there are 3 options: heart surgery, thrombolysis, and/or anticoagulation. The last 2 are more prevalent in posterior embolism at the start of therapy as compared with surgery; furthermore, the latter presents lower probability of systemic embolism and death, versus anticoagulation alone, in addition to shunt closure. Thrombolysis could be the initial therapeutic approach in case of severe PTE, with or without intracardiac thrombi; the association with systemic embolism is of 23.5%.^{5,15-17}

Conclusions

The association between patent foramen ovale and impending paradoxical embolism is infrequent. Its presentation during pregnancy is even rarer, but its impact among the young and healthy population presents with a high morbidity and mortality for both the mother and the child, leading to a social and economic impact resulting from the considerable costs of care.

The existing evidence about treatment to date is weak, though surgical management is apparently favored over thrombolysis or anticoagulation, in addition to the benefit of a definite surgical solution to the patent foramen ovale.

Ethical responsibilities

Protection of people and animals. The authors declare that no human or animal experiments were conducted for this research.

Confidentiality of the data. The authors declare that they have adhered to their institutional protocols regarding the publication of patient information.

Right to privacy and informed consent. The authors have obtained the informed consent of patients and/or subjects mentioned in the article. The consent forms are in custody of the correspondent author.

Funding

No sponsorship was received for this article.

Conflicts of interest

The authors have no conflict of interest to disclose.

References

1. Erkut B, Kocak H, Becit N, et al. Massive pulmonary embolism complicated by a patent foramen ovale with straddling thrombus: report of a case. *Surg Today* 2006;36:528–533.
2. Cruz-Gonzalez I, Solis J, Inglessis-Azuaje I, et al. Patent foramen ovale: current state of the art. *Rev Esp Cardiol* 2008;61:738–751.
3. Parunov LA, Soshitova NP, Ovanesov MV, et al. Epidemiology of venous thromboembolism (VTE) associated with pregnancy. *Birth Defects Res C Embryo Today* 2015;105:167–184.
4. Myers PO, Bounameaux H, Panos A, et al. Impending paradoxical embolism: systematic review of prognostic factors and treatment. *Chest* 2010;137:164–170.
5. Myers PO, Fassa AA, Panos A, et al. Life-threatening pulmonary embolism associated with a thrombus straddling a patent foramen ovale: report of a case. *J Card Surg* 2008;23:376–378.
6. Mathew R, Roy WE. Paradoxical massive pulmonary embolism with a straddling thrombus across a patent foramen ovale. *Intensive Care Med* 2014;40:891–892.
7. Debonnaire P, Onsea K, Desmet W. Straddling thrombus through a patent foramen ovale secondary to saddle embolism. *Acta Clin Belg* 2011;66:243.
8. Jaramillo MH. Patent foramen ovale and cryptogenic stroke. Echocardiography role and state of the art. *Rev Colomb Cardiol* 2008;15:8.
9. Mayorga LE, Clavijo C. Imminent paradoxical embolism evidenced by echocardiography in patients with patent foramen ovale. *Rev Colomb Cardiol* 2008;15:3.
10. Olivencia L, Soto JM, Martín de la Fuente P. Paradoxical embolism through permeable foramen ovale coincident with pulmonary embolism. *Med Intensiva* 2012;36:450–451.
11. Padilla Pérez AI, de la Torre Fernández de Vega J, Carballo Lorenzo J, Padrón Pérez E. Ischemic Stroke in secondary postpartum to paradoxical embolism. *Rev Chil Obstet Ginecol* 2010;75:4.
12. Miranda A, Franco S, Uribe W, Duque M, Femenía F, Baranchuk A. High-risk massive pulmonary thromboembolism associated with patent foramen ovale. *Medicina* 2012;72:2.
13. Reyes L, Muñoz L, CE, M. Pulmonary embolectomy and cardiopulmonary bypass during pregnancy. *Rev Colomb Anestesiología* 2013;41:4.
14. Offin MD, Menachem J, Squillante C, et al. Association among hypoxemia, patent foramen ovale, and mediastinal germ cell tumor: a case report. *Ann Intern Med* 2015;163:243–244.
15. Mintz R, Brody K. Impending paradoxical embolism: a case report. *J Emerg Med* 2013;45:19–21.
16. Nemoto A, Kudo M, Yamabe K, et al. Successful surgical treatment for a thrombus straddling a patent foramen ovale: a case report. *J Cardiothorac Surg* 2013;8:138.
17. Fauveau E, Cohen A, Bonnet N, et al. Surgical or medical treatment for thrombus straddling the patent foramen ovale: impending paradoxical embolism? Report of four clinical cases and literature review. *Arch Cardiovasc Dis* 2008;101:637–644.