



Colombian Journal of Anesthesiology

Revista Colombiana de Anestesiología

www.revcolanest.com.co

OPEN

Wolters Kluwer

CASE REPORT

Anesthesia for intrauterine myelomeningocele correction: first successful experience in Peru. Case report

Anestesia para corrección intraútero de mielomeningocele: Primera experiencia exitosa en Perú. Reporte de caso

Keywords: Relaxation, Anesthesia, Meningomyelocele, Case Reports, Peru

Palabras clave: Relajación, Anestesia, Mielomeningocele, Informes de Casos, Perú

Marjorie Lisseth Calderón-Lozano^a, Pedro Saldaña-Montes^a, Renato Moreno-Gonzales^a, Walter R. Ventura-Laveriano^b

^a Department of Anaesthesiology, Analgesia and Resuscitation, Instituto Nacional Materno Perinatal, Lima, Peru

^b Instituto Nacional Materno Perinatal, Lima, Peru.

Abstract

Introduction: In pregnancies with a diagnosis of fetal myelomeningocele (MMC), studies have shown that prenatal correction, as compared with postnatal correction, results in better outcomes in infancy, requiring less ventriculoperitoneal shunts, and resulting in improved motor function of the lower limbs. However, maternal morbidity, the risk of uterine repair dehiscence, uterine rupture secondary to hysterotomy, and the need for cesarean section are all increased. This case report is the first successful experience of intrauterine repair of a MMC in Peru.

Case presentation: We describe the case of a primigravida at 25 weeks of gestation with a diagnosis of fetal malformation (MMC and Arnold Chiari II syndrome) taken to intrauterine correction of the neural tube defect under general anesthesia plus epidural analgesia.

Conclusion: The use of total intravenous anesthesia associated with nitroglycerine infusion for uterine relaxation, ethyl-ephedrine infusion to maintain maternal hemodynamic stability,

and adequate postoperative pain management with epidural analgesia was successful in this case.

Resumen

Introducción: En los embarazos con diagnóstico de Mielomeningocele fetal, los estudios han demostrado que la corrección prenatal conlleva a mejores resultados en la infancia que la corrección postnatal, requiriendo menos derivaciones ventrículo peritoneales y mejor función motora de miembros inferiores. Sin embargo se incrementa la morbilidad materna, el riesgo de dehiscencia de histerorrafa, ruptura uterina secundaria a la histerotomía y la necesidad de parto por cesárea.

El presente reporte de caso es la primera experiencia exitosa de reparación intraútero de MMC en Perú.

Presentación del caso: Describimos el caso de una primigesta de 25 semanas de gestación, con diagnóstico de malformación fetal (Mielomeningocele y Síndrome de Arnold Chiari II) en quien

How to cite this article: Calderón-Lozano ML, Saldaña-Montes P, Moreno-Gonzales R, Ventura-Laveriano WR. Anesthesia for intrauterine myelomeningocele correction: first successful experience in Peru. Case report. Colombian Journal of Anesthesiology. 2018;46:336-340.

Read the Spanish version of this article at: <http://links.lww.com/RCA/A129>.

Copyright © 2018 Sociedad Colombiana de Anestesiología y Reanimación (S.C.A.R.E.). Published by Wolters Kluwer. This is an open access article under the CC BY-NC-ND license (<http://creativecommons.org/licenses/by-nc-nd/4.0/>).

Correspondence: Departamento de Anestesiología, Analgesia y Reanimación, Instituto Nacional Materno Perinatal, Av. Miroquesada 941, Lima, Perú. E-mail: marjorie_163@hotmail.com (M.L. Calderón-Lozano)

Colombian Journal of Anesthesiology (2018) 46:4

<http://dx.doi.org/10.1097/CJ9.0000000000000066>

se realizó una corrección intraútero del defecto neural y cuya técnica anestésica fue anestesia general más analgesia epidural.

Conclusiones: El uso de anestesia total intravenosa asociado a la infusión de nitroglicerina para la relajación uterina, la infusión de etilefrina para mantener la estabilidad hemodinámica materna y el adecuado manejo del dolor postoperatorio vía epidural fue exitoso en este caso.

Introduction

Myelomeningocele (MMC) is the most common and severe form of spina bifida, and it affects 1–10 out of every 1000 live births in the world. This congenital defect occurs at approximately 4 weeks of gestation and is characterized by incomplete neural tube closure. This results in nerve fibers being in direct contact with amniotic fluid, rubbing constantly against the walls of the uterus.¹⁻³

Patients with MMC have multiple complications, including hydrocephalus, motor impairment of the lower limbs, and bladder and gut dysfunction; orthopedic and neurocognitive abnormalities and abnormalities related to the Chiari type II malformation; and emotional and social changes.^{2,4}

With the boom of fetal surgery, intrauterine MMC repair emerged as an option to limit damage and complications associated with it.⁵ MOMS (Management of Mielomeningocele Study) was first put into motion in 2003 with the aim of comparing outcomes between intrauterine repair and conventional postnatal repair over an 8-year period. Results showed that prenatal surgery reduced the need for cerebrospinal fluid shunting, led to improved motor function, and reduced hindbrain herniation. However, it was also associated with a higher risk of preterm delivery and uterine dehiscence during cesarean section.⁶

Advancements in fetal surgery create new challenges for anesthetists, whose role is critical for the success of the surgery. This case report is the first successful experience in intrauterine MMC repair in Peru.

Case presentation

A 27-year-old primigravida at 25 weeks of gestation with fetal diagnosis of open spina bifida (MMC), ventriculomegaly, and Arnold Chiari II syndrome, scheduled for intrauterine MMC correction. Figure 1 shows the magnetic resonance image revealing the extensive fetal vertebral defect. The patient had no relevant personal history and the physical examination found American Society of Anesthesiologists (ASA) Physical Status classification II, weight 84 kg, height 169 cm, body mass index 29, blood pressure (BP) 110/70 mm Hg, heart rate 74/min, absent difficult airway predictors, and no abnormal cardiopulmonary findings. Laboratory tests included hemoglobin 12.3 g/dL, prothrombin time (PT) 11.5 seconds, partial thromboplastin time (PTT) 26.2 seconds, fibrinogen

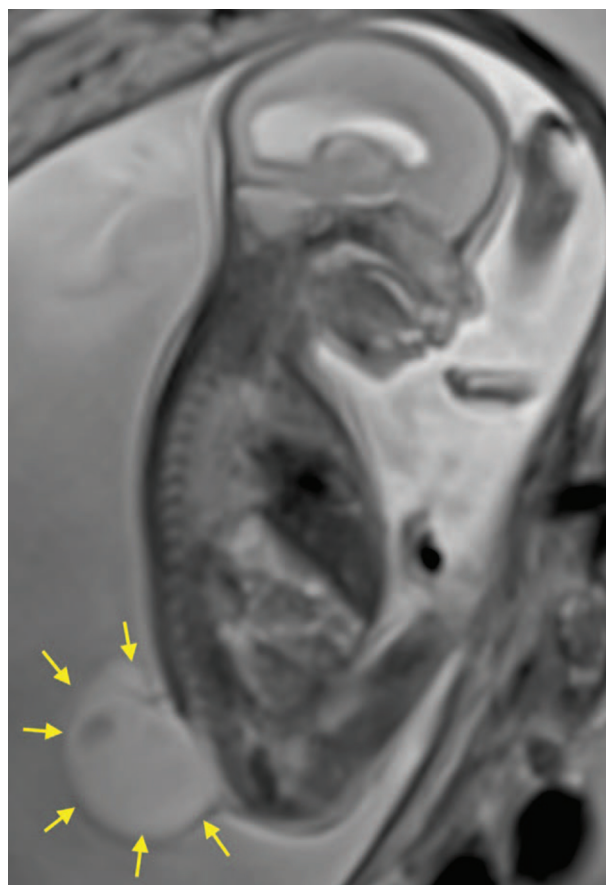


Figure 1. Fetal nuclear magnetic resonance showing extensive spinal injury.

Source: Authors.

310 mg/dL, and platelet count 234,000/ μ L. The patient and her spouse were explained the anesthetic techniques with their risks and benefits and it was decided to use an epidural catheter for postoperative pain management, and general intravenous anesthesia, and the informed consent was obtained.

In the operating room, a thermal blanket was used, a peripheral No. 18 line was placed in the left arm and the patient was administered ranitidine 50 mg, metoclopramide 10 mg, and cefazolin 2 g. A second intravenous No. 16 line was placed immediately in the same arm. Basic ASA monitoring was applied, and difficult airway devices and aspiration catheter were prepared. The patient was then placed in a left lateral decubitus position, asepsis and antisepsis were performed, and the epidural space was identified 5 cm from the skin surface using a No. 18 Tuohy needle and the technique of intermittent loss of resistance, at the level of L2–L3. The No. 20 multiport epidural catheter was then put in place. A test dose was given using 3 mL of 2% lidocaine with epinephrine 1 in 200,000, with a negative result.

The patient was then positioned in supine decubitus and an infusion with remifentanyl 1.5 ng/ml concentration in the effect site (Ce) was initiated using target control

infusion (TCI). After asepsis and antisepsis and local anesthetic infiltration, an arterial catheter was placed in the right arterial artery. Following preoxygenation, rapid sequence induction was initiated with remifentanyl 5 ng/mL Ce by TCI, propofol 4 μ g/mL Ce by TCI and rocuronium 1 mg/kg. The Sellick maneuver was performed, achieving intubation on the first attempt, and with no significant changes in hemodynamic parameters. The remifentanyl and propofol infusion was set to reach a bi-spectral index between 40 and 60, and a fluctuation in hemodynamic parameters of less than 20% in relation to initial values. In turn, the remifentanyl infusion was used to achieve transplacental fetal anesthesia. Surgery was initiated and at the time of uterine exposure to access the fetus, a nitroglycerine infusion was used ranging between 1 μ g/kg/minute and a maximum of 6 μ g/kg/minute to favor uterine relaxation and allow neurorrhaphy by the neurosurgeon, as illustrated in Fig. 2. Ethylephrine infusion was used at a dose of 2.5–5 μ g/kg/minute to maintain systolic BP >90 mm Hg and mean arterial pressure >60 mm Hg, and a crystalloid infusion was administered at a rate of 20 mL/hour. The nitroglycerine infusion was interrupted at the end of the hysterorrhaphy, and a bolus dose of atosiban 6.75 mg was administered followed by a 300 μ g/minute infusion. At the end of surgery, 0.125% bupivacaine plus fentanyl 50 μ g were administered through the epidural catheter in a total volume of 16 cm³. Analgesia was supplemented with the administration of metamizole

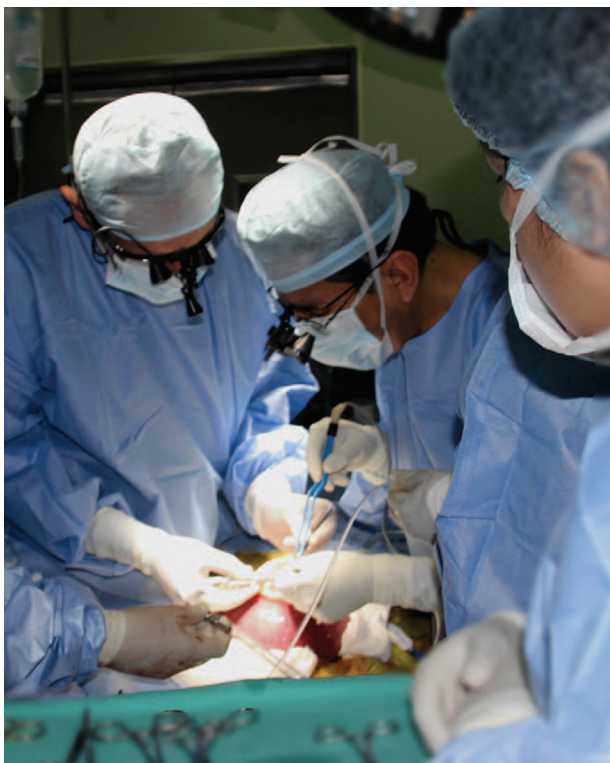

Figure 2. Adequate uterine relaxation that allows neurorrhaphy. Source: Authors.

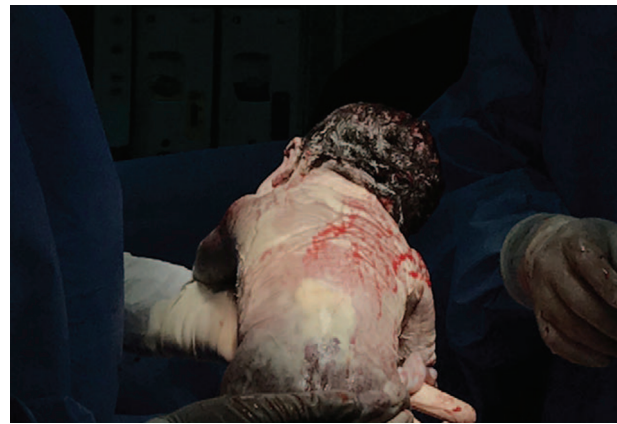

Figure 3. Newborn with fully healed spine. Source: Authors.

2-g intravenous and the patient was then extubated following reversal with neostigmine and atropine, with full recovery from total neuromuscular blockade.

The surgery was uneventful. Postoperative analgesia was managed with a continuous peridural infusion of bupivacaine and fentanyl, plus tocolytic drugs during the first 48 hours. The patient remained in the intensive care unit during the first 3 postoperative days with intermittent pneumatic compression to prevent thromboembolic events, and was then transferred to the ward where she remained until discharge on postoperative day 7. No postoperative complications were reported. Laboratory test results at discharge were hemoglobin 12 g/dL, PT 11 seconds, PTT 26 seconds, fibrinogen 387 mg/dL, platelet count 230,000/ μ L.

The patient was readmitted at 37 weeks of gestation for elective cesarean section using spinal-epidural technique, with no intraoperative or postoperative complications, and was delivered of a newborn adequate for gestational age, weighing 2879 g, with 1 and 5 minute Apgar scores of 8 and 9, respectively. Figure 3 shows the neonate with completely healed spine. Assessment of the newborn by the pediatric neurologist at 24 hours found no hydrocephalus or Arnold Chiari II malformation, and discreet lower limb motion.

Discussion

The exact incidence of neural tube defects (NTD) in our country is unknown. Tarqui-Mamani et al described an overall in-hospital NTD incidence rate of 13.6 for every 10,000 live births between 2001 and 2005 at the National Maternal Perinatal Institute in, Lima, Peru, and the most frequent form of spina bifida was MMC with an overall incidence rate of 7.4 for every 10,000 live births.⁷ Following the national intervention of wheat flour fortification with folic acid, the overall incidence rate of NTD and MMC dropped to 8.73 and 6.0 for every 10,000 live births, respectively, in the period between 2006 and 2010.⁸

In the MOMS study, apart from the benefits of prenatal repair for the neonate, it was found that there was increased maternal morbidity including the risk of hysterorrhaphy dehiscence, uterine rupture secondary to hysterotomy, and the need for cesarean section in all subsequent pregnancies.⁹ For this reason, risk/benefit must be assessed on an individual basis, taking into account the considerations from all the specialties involved as well as patient-related factors.

A key point is the need for uterine relaxation to create optimal conditions for surgery and to maintain adequate uteroplacental perfusion, and it is worth noting that neuroaxial anesthesia does not provide uterine relaxation.

In normal conditions, the uterine muscle contracts in response to the stimulus. This myometrial contractility is inhibited by calcium-sensitive potassium channels modulated by volatile anesthetics.¹⁰ Many authors use and recommend the use of high-dose volatile anesthetics (minimum alveolar concentration > 2) to maintain uterine relaxation.¹¹ Potential disadvantages of this technique are hemodynamic instability and excess uterine bleeding. Moreover, high-dose inhaled agents have been associated with significant fetal cardiac dysfunction and a risk of neuronal apoptosis described in animal studies,¹² whereas a study by Chatterjee et al¹³ showed that the use of propofol with desflurane minimized fetal cardiac dysfunction.

Another option to maintain uterine relaxation is the use of a nitroglycerine infusion. Nitroglycerine induces smooth muscle relaxation and produces generalized vasodilation.¹⁴ In obstetrics, it has been widely used in 50 to 100 µg boluses in cases of placental retention. However, its administration increases the incidence of maternal pulmonary edema during these types of surgeries, probably because it acts as a nitric oxide donor, creating nitrite peroxide which harms type II pneumocytes.⁹ This constitutes an additional challenge in terms of monitoring and restricted fluid administration. Despite these considerations, we selected the latter option given the quick reversibility of the effect and independence from the depth of anesthesia.

Any drug used to maintain uterine relaxation will give rise to significant maternal hypotension given uteroplacental perfusion dependency and inability to autoregulate, hence the importance of using vasopressors.

Different vasopressors are used in obstetric anesthesia, phenylephrine being the drug of choice due to its lower repercussions on fetal pH as compared with ephedrine. Belzarena¹⁵ compared ephedrine and ethylephrine and found no significant difference between their use and neonatal or maternal outcomes in patients under spinal anesthesia for cesarean section. In their study on the use of ethylephrine and phenylephrine in spinal anesthesia, Bolaños et al¹⁶ found them to be equally effective in the treatment of hypotension associated with spinal anesthesia for cesarean section, with no differences in fetal outcomes. Based on these results, and given the unavail-

ability of phenylephrine in the country, we decided to use ethylephrine infusion.

Finally, fetal anesthesia during this procedures is provided by transplacental crossing of drugs such as volatile anesthetics and opioids, among others.⁹ In vitro studies have shown that inhaled anesthetics (sevoflurane) produce a dose-dependent contractile depression of the myocardium, which may be reduced when used together with intravenous agents.¹⁷ We selected the transplacental route with the use of remifentanyl.

The main strengths of this study include coordinated team work and the availability of equipment, monitors, and supplies for this type of surgery. The main limitation of this report is the description of anesthetic management in a single case.

Conclusion

Each and every detail of the anesthetic management will contribute to the success or failure of this type of surgery. It is clear to us that the understanding of maternal and fetal physiology is the starting point for continuing with this type of procedure, avoiding potential maternal complications and improving fetal prognosis. The use of total intravenous anesthesia associated with nitroglycerine infusion for uterine relaxation, ethylephrine infusion to maintain maternal hemodynamic stability, and adequate postoperative pain management with epidural analgesia was successful in this case.

Ethical responsibilities

Human and animal protection. The authors declare that no experiments were conducted in humans or animals for this research.

Data confidentiality. The authors declare having followed the protocols of their institution regarding disclosure of patient information.

Right to privacy and informed consent. The authors obtained the informed consent from the patient and/or subjects mentioned in this article. The informed consent form is available from the corresponding author.

Acknowledgments

We are grateful to Dr Juan Devoto Garcés, Assistant physician of the Anaesthesiology, Analgesia and Resuscitation Department of Clínica Las Condes, Santiago de Chile.

Funding

The study was funded by the authors.

Conflict of interest

The authors have no conflicts of interest to disclose.

References

1. Phillips LA, Burton JM, Evans SH. Spina bifida management. *Curr Probl Pediatr Adolesc Health Care* 2017;47:173–177.
2. Miller RS, Kuller JA. ACOG Committee opinion: maternal-fetal surgery for myelomeningocele. *Obstet Gynecol* 2017;130:e164–e167.
3. Carreras E, Maroto A, Arévalo S, et al. Prenatal treatment of myelomeningocele. *Diagnprenat* 2012;23:148–153.
4. Heuer GG, Moldenhauer JS, Adzick NS. Prenatal surgery for myelomeningocele: review of the literature and future directions. *Childs Nerv Syst* 2017;33:1149–1155.
5. Kabagambe SK, Chen YJ, Vanover MA, et al. New directions in fetal surgery for myelomeningocele. *Childs Nerv Syst* 2017;33:1185–1190.
6. Adzick S, Thorn E, Spong C. A randomized trial of prenatal versus postnatal repair of myelomeningocele. *N Engl J Med* 2011;364:993–1004.
7. Tarqui CB, Sanabria HA, Lam NM, et al. Incidence of neural tube defects in the National Maternal Perinatal Institute of Lima. *Rev Chil Salud Pública* 2009;13:82–89.
8. Sanabria HA, Tarqui CB, Arias J, et al. Impact of fortifying wheat flour with folic acid on neural tube defects in Lima, Peru. *An Fac Med* 2013;74:175–180.
9. Ferschl M, Ball R, Lee H, et al. Anesthesia for in utero repair of myelomeningocele. *Anesthesiology* 2013;118:1211–1223.
10. Kafali H, Kaya T, Gürsoy S, et al. The role of K(+) channels on the inhibitor effect of sevoflurane in pregnant rat myometrium. *Anesth Analg* 2002;94:174–178.
11. Okutomi T, Saito M, Kuczkowski KM. The use of potent inhalation agents for the ex-utero intrapartum treatment (EXIT) procedures: what concentrations? *Acta Anaesthesiol Belg* 2007;58:97–99.
12. Zheng SQ, An LX, Cheng X, et al. Sevoflurane causes neuronal apoptosis and adaptability changes of neonatal rats. *Acta Anaesthesiol Scand* 2013;57:1167–1174.
13. Chatterjee D, Wood CL, Howley LW, et al. Use of intravenous anesthetics minimizes fetal cardiac dysfunction during prenatal myelomeningocele repair. *Am J Obstet Gynecol* 2016;214:103.
14. Saroa R, Sachan S, Palta S, et al. Obstetric use of nitroglycerin: anesthetic implications. *Saudi J Anaesth* 2013;7:350–352.
15. Belzarena SD. Ephedrine and etilefrine as vasopressor to correct maternal arterial hypotension during elective cesarean section under spinal anesthesia. *Rev Bras Anesthesiol* 2006;56:223–229.
16. Bolaños D, Fonseca NJ, Socha NI, et al. Etilefrine vs. phenylephrine for hypotension during spinal anesthesia for cesarean section: multicenter, randomized, double blind controlled clinical trial. *Rev Colomb Anesthesiol* 2016;44:89–96.
17. Devoto JC, Alcalde JL, Otayza F, et al. Anesthesia for myelomeningocele surgery in fetus. *Childs Nerv Syst* 2017;33:1169–1175.