

Revista Colombiana de Anestesiología

Colombian Journal of Anesthesiology

www.revcolanest.com.co



Case report

Anaesthetic management for emergent upper limb trauma surgery in a 23-week pregnant woman: Role of ultrasound-guided infraclavicular brachial plexus block. Case report[☆]



Rosana Guerrero-Domínguez^{a,*}, Daniel López-Herrera-Rodríguez^a,
Jesús Fernández-López^b, Ángeles Luengo^a, Ignacio Jiménez^c

^a MD, Anaesthetist, Hospitales Universitarios Virgen del Rocío, Sevilla, Spain

^b Anaesthesia Resident, Hospitales Universitarios Virgen del Rocío, Sevilla, Spain

^c PhD, Anaesthetist, Hospitales Universitarios Virgen del Rocío, Sevilla, Spain

ARTICLE INFO

Article history:

Received 27 August 2013

Accepted 24 March 2014

Available online 20 May 2014

Keywords:

Pregnant women

Anesthesia, conduction

Brachial plexus

Nerve block

Analgesia

ABSTRACT

We describe the anaesthetic management of a 34-year-old woman at 23 weeks of gestation with a forearm tendon and vascular injury who required an emergent surgical repair. Brachial plexus nerve block avoids the potential risk of failed intubation and aspiration in addition to reducing the exposure of the foetus to potentially teratogenic drugs. Whenever feasible, a regional anaesthetic technique should be used. If general anaesthesia is mandatory, a rapid sequence induction is required. A multidisciplinary approach needs to be established early in the management of these patients. Anaesthetists must provide safe anaesthesia for both mother and child by maintaining adequate maternal oxygenation for avoiding foetal asphyxia.

© 2013 Sociedad Colombiana de Anestesiología y Reanimación. Published by Elsevier España, S.L. All rights reserved.

Manejo anestésico para la cirugía urgente traumatológica en miembro superior en una gestante de 23 semanas: rol del bloqueo ecoguiado del plexo braquial mediante abordaje infraclavicular. Reporte de caso

RESUMEN

Describimos el manejo anestésico de una mujer de 34 años en su 23 semana de gestación con una lesión vascular y tendinosa de antebrazo que requirió una reparación quirúrgica urgente. El bloqueo nervioso del plexo braquial evita el riesgo potencial de intubación fallida

Palabras clave:

Mujeres embarazadas

Anestesia de conducción

[☆] Please cite this article as: Guerrero-Domínguez R, López-Herrera-Rodríguez D, Fernández-López J, Luengo Á, Jiménez I. Manejo anestésico para la cirugía urgente traumatológica en miembro superior en una gestante de 23 semanas: rol del bloqueo ecoguiado del plexo braquial mediante abordaje infraclavicular: reporte de caso. Rev Colomb Anestesiología. 2014;42:234-237.

* Corresponding author at: Avda Ramón Carande, No11, 4oE, 41013 Sevilla, Spain.

E-mail address: rosanabixi7@hotmail.com (R. Guerrero-Domínguez).

Plexo braquial
Bloqueo nervioso
Analgesia

y de broncoaspiración, además de reducir la exposición fetal a fármacos potencialmente teratógenos. Mientras sea posible una técnica anestésica regional, debería ser usada. Si es inevitable una anestesia general, se requiere una inducción de secuencia rápida. Un abordaje multidisciplinar debe ser establecido en el manejo de estas pacientes. Los anestesiólogos deben proporcionar una anestesia segura tanto para la madre como para el feto manteniendo una oxigenación materna adecuada para evitar la asfixia fetal.

© 2013 Sociedad Colombiana de Anestesiología y Reanimación. Publicado por Elsevier España, S.L. Todos los derechos reservados.

Introduction

Anaesthetic techniques used in obstetric patients requiring emergent surgical interventions pose a challenge to the anaesthetist. In the second trimester, the teratogenic effects of certain drugs used in our daily practice^{1,2} may compromise foetal development and lead to the occurrence of different types of malformations depending on gestational age. Locoregional procedures are the options of choice in these patients.³

Clinical case

We present the case of a 34-year-old pregnant woman at 23 weeks of gestation who was involved in an automobile accident and sustained blunt and penetrating trauma to the left forearm with subsidiary tendon and vascular injuries, requiring urgent intervention. She had no other remarkable personal history except for uncertainty regarding the fasting period. After the assessment by a multidisciplinary team consisting of orthopaedic surgeons, anaesthetists and a gynaecologist, it was decided to take the patient to emergent surgery using ultrasound-guided infraclavicular brachial plexus nerve block.

Since arrival to our centre, the patient remained haemodynamically stable. Airway exploration revealed a Mallampati II airway, normal cervical extension, and unrestricted mouth opening. The patient reported severe pain and functional impairment of the forearm, together with active bleeding at the wound site. Whole blood count showed normal results for red blood cells, leukocytes, platelets and coagulation tests. The gynaecological ultrasound showed a normally developing pregnancy for the reported gestational age.

In the operating room, considering the gestational age of more than 20 weeks, the patient was placed in left lateral decubitus in order to reduce aortocaval compression and improve venous return. Prophylactic amoxicillin was given 30 min before the start of the surgical intervention. After usual non-invasive monitoring of blood pressure, electrocardiogram and pulse oximetry, the patient received fentanyl 100 µg for anxiety control. Nasal prongs were used at a flow rate of 2 l/min. Given the gestational age, the obstetric team decided not to use intraoperative foetal heart rate (FHR) monitoring.

The patient was then placed in supine decubitus with the arm in adduction in order to use a coracoid approach technique. The axillary artery was localized under ultrasound guidance and the pectoralis major, pectoralis minor, lateral, posterior and medial brachial plexus fascicles were identified

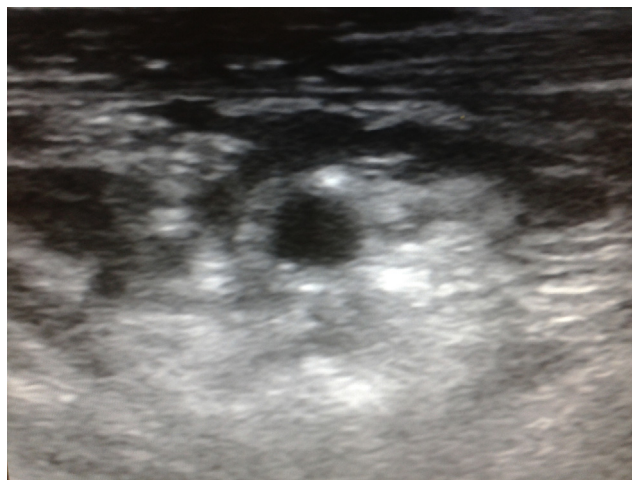


Fig. 1 – Ultrasound image of the brachial plexus at the infraclavicular level showing the distribution of the local anaesthetic to the lateral, posterior and medial fascicles. Source: Authors.

around the artery. With the probe in a vertical position, the in-plane approach was used to deliver 20 ml of 1.5% mepivacaine distributed between the three brachial plexus fascicles; the ultrasound showed an anechoic image of the local anaesthetic injection (Fig. 1).

During the procedure consisting of tendon repair and vascular anastomosis (Fig. 2), the patient remained haemodynamically stable, with systolic blood pressures between 110 and 120 mmHg, heart rate of 80–90 beats per minute and peripheral oxygen saturation (SpO₂) of 99–100%. Analgesia and motor block were adequate throughout, with no need for adjuvant analgesia or sedation. After 140 min of the surgical intervention and completion of the procedure, the patient was transferred to the recovery room where she evolved favourably.

Discussion

Non-obstetrical surgery during pregnancy is relatively common, with an incidence of 0.15% of the pregnant patients.⁴⁻⁶ The most frequent indications for surgery during pregnancy are acute abdominal infections (such as appendicitis or cholecystitis), trauma and tumours.^{4,7} However, any type of emergent surgical procedure may be required during pregnancy.⁴

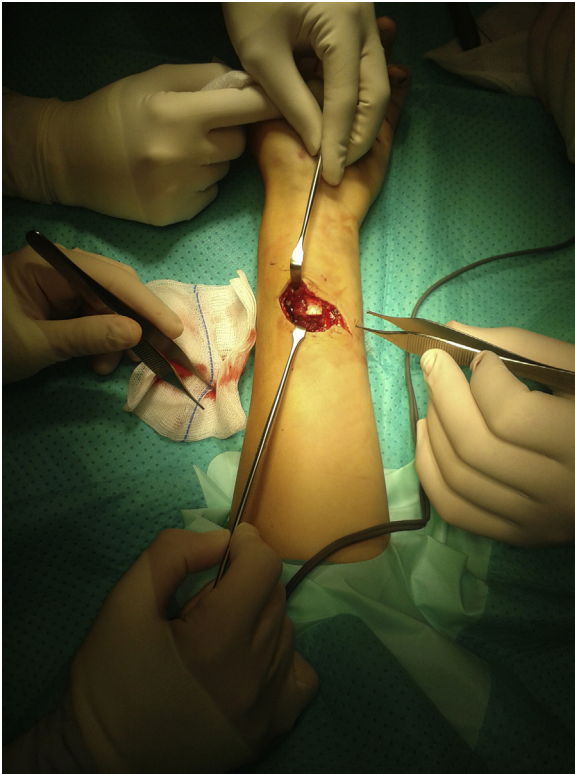


Fig. 2 – Intraoperative image of the surgical repair of the vascular and tendinous injuries in the anterior aspect of the forearm.
Source: Authors.

Performing a surgical intervention in obstetric patients has important anaesthetic implications⁸ related primarily to physiological changes, the potential teratogenic effect of the drugs used, and haemodynamic alterations associated with anaesthesia induction or maintenance which might compromise foetal wellbeing.^{1,2} Anatomic and physiological changes⁹ as a result of oedema, and friable upper airway tissues, may hamper ventilation and orotracheal intubation.³ Moreover, the pregnant uterus is the most important consideration for “full stomach” after 20 weeks of gestation.^{1,2}

Anxiolytic premedication is essential,² considering that increased adrenergic activity in the context of a stressful situation, as well as the associated hyperventilation, may result in uterine arterial vasoconstriction and reduced utero-placental blood flow because of the chronic physiologic respiratory alkalosis.^{1,2,5}

The use of locoregional techniques avoids the potential risk of failed intubation and aspiration, and also limits foetal exposure to potentially teratogenic drugs.^{2,10,11} In those cases where the use of general anaesthesia is unavoidable, rapid sequence induction is recommended^{1,2,4}; the strategy for approaching the airway must be planned together with a back-up plan in the event the initial approach fails. As for intraoperative FHR monitoring, its usefulness is controversial before 25 weeks of gestation^{2,4,12-14} because in the context of general anaesthesia¹⁵ there could be variability changes due to the non-pathological effect of the anaesthetic drugs on the

foetal autonomic nervous system.² Although FHR monitoring after 25 weeks is an important indicator of adequate utero-placental perfusion,⁴ some authors consider that, before that gestational age, it may give rise to confusion regarding the detection of compromised foetal wellbeing.²

Anaesthetic management of patients with upper limb trauma may be accomplished by means of brachial plexus blocks through the inter-scalene, axillary, supraclavicular and infraclavicular approaches.¹⁶ Ultrasound-guided locoregional blocks¹⁷ have grown in popularity¹⁸ because they allow direct visualization of the nerve structures, the needle, and the adjacent structures, but most importantly, controlled distribution of the local anaesthetic.¹⁸ The infraclavicular brachial plexus block has been shown to be effective for elbow, forearm and hand surgery.¹⁹ The advantages of this approach include the ability to perform the block with the patient’s arm in any position, the fact that it points away from the neurovascular structures of the neck, and the ability to fix a continuous brachial plexus catheter to the chest wall^{18,20,21}. Ultrasound visualization of the anatomic structures improves our success with the infraclavicular brachial plexus block, as it helps to reduce complications such as intraneural injection of local anaesthetics and the risk of pneumothorax.^{18,22}

Our main objective during the surgical intervention is to maintain maternal haemodynamic stability,^{1,2,4,23} ensuring adequate utero-placental perfusion and foetal oxygenation in order to avoid periods of hypotension. We recommend the use of locoregional anaesthetic techniques in order to avoid the use of potentially teratogenic drugs^{4,9} and airway manipulation, given the potentially difficult airway and the increased risk of aspiration.^{1,2,4}

Funding

None.

Conflicts of interest

There are no conflicts of interest.

REFERENCES

1. Ní Mhuireachtaigh R, O’Gorman DA. Anesthesia in pregnant patients for nonobstetric surgery. *J Clin Anesth.* 2006;18:60–6.
2. Reitman E, Flood P. Anaesthetic considerations for non-obstetric surgery during pregnancy. *Br J Anaesth.* 2011;107 suppl. 1:i72–8.
3. Bansal T, Kumar P, Hooda S. Anestesia regional: todavía una alternativa adecuada en la parturienta con obesidad mórbida. *Rev Colomb Anestesiología.* 2013;41:302–5.
4. Van de Velde M, De Buck F. Anesthesia for non-obstetric surgery in the pregnant patient. *Minerva Anestesiología.* 2007;73:235–40.
5. Brodsky JB, Cohen EN, Brown Jr BW, Wu ML, Witcher C. Surgery during pregnancy and fetal outcome. *Am J Obstet Gynecol.* 1980;138:165–7.
6. Kort B, Katz VL, Watson WJ. The effect of nonobstetric operation during pregnancy. *Surg Gynecol Obstet.* 1993;177:371–6.

7. Naughton NN, Cohen SE. Nonobstetric surgery during pregnancy. In: Chestnut DH, editor. *Obstetric anesthesia: principles and practice*. 3rd ed. Philadelphia: Elsevier Mosby; 2004. p. 255-72.
8. Crowhurst JA. Anaesthesia for non obstetric surgery during pregnancy. *Acta Anaesthesiol Belg*. 2002;53:295-7.
9. Cohen SE. Nonobstetric surgery during pregnancy. In: Chestnut DH, editor. *Obstetric anesthesia: principles and practice*, vol. 7, 2nd ed. St. Louis (Mo): Mosby; 1999. p. 279.
10. Kress HG. Effects of general anaesthetics on second messenger systems. *Eur J Anaesthesiol*. 1995;12:83-97.
11. Sturrock JE, Nunn JF. Mitosis in mammalian cells during exposure to anesthetics. *Anesthesiology*. 1975;43:21-33.
12. Wang LP, Paech MJ. Neuroanesthesia for the pregnant woman. *Anesth Analg*. 2008;107:193-200.
13. Kuczkowski KM. Nonobstetric surgery during pregnancy: what are the risks of anesthesia? *Obstet Gynecol Surv*. 2004;59:52-6.
14. Horrigan TJ, Villareal R, Weinstein L. Are obstetrical personnel required for intraoperative fetal monitoring during nonobstetric surgery? *J Perinatol*. 1999;19:124-6.
15. ACOG, ACOG Committee on Obstetric Practice. Nonobstetric surgery in pregnancy. *Obstet Gynecol*. 2003;102:431.
16. Dardon JC, Herrera L, Perez A. Estudio comparativo, prospectivo, longitudinal y aleatorio de tres técnicas de bloqueos cervicobraquiales para cirugía de extremidades superiores. *Rev Mex Anest*. 2000;23:7-10.
17. Vásquez MI, Jiménez AM, Aguirre OD, González MP, Ríos AM. Bloqueo supraclavicular bilateral con ecografía. *Rev Colomb Anesthesiol*. 2012;40:304-8.
18. Ortega Romero A, de Diego Isasa D, del Olmo Rodríguez C, Maroto Ramos E, Rouco Gil R. Ecografía portátil en anestesia regional: bloqueos del plexo braquial. *Rev Esp Anesthesiol Reanim*. 2008;55:294-303.
19. Wilson JL, Brown DL, Wong GY, Ehman RL, Cahill DR. Infraclavicular brachial plexus block: parasagittal anatomy important to the coracoid technique. *Anesth Analg*. 1998;87:870-3.
20. Perlas A, Chan VW, Simons M. Brachial plexus examination and localization using and electrical stimulation. *Anesthesiology*. 2003;99:429-35.
21. Marhofer P, Greher M, Kapral S. Ultrasound guidance in regional anaesthesia. *Br J Anaesth*. 2005;94:7-17.
22. Bigeleisen P. Nerve puncture and apparent intraneural injection during ultrasound-guided axillary block does not invariably result in neurologic injury. *Anesthesiology*. 2006;105:779-83.
23. Naughton NN, Chitra CS. Nonobstetric surgery during pregnancy. In: Chestnut DH, editor. *Obstetric anesthesia: principles practice*. Philadelphia: Elsevier Mosby; 2004. p. 255-72.